






Review

Oral Manifestations in Patients with Glycogen Storage Disease: A Systematic Review of the Literature

Antonio Romano ^{1,†}, Diana Russo ^{1,†} , Maria Contaldo ¹ , Dorina Lauritano ² ,
Fedora della Vella ³ , Rosario Serpico ¹, Alberta Lucchese ^{1,*} and Dario Di Stasio ¹ 

¹ Multidisciplinary Department of Medical-Surgical and Dental Specialties, University of Campania “L. Vanvitelli”, Via Luigi De Crecchio 6, 80138 Naples, Italy; antonio.romano4@unicampania.it (A.R.); dianarusso96@gmail.com (D.R.); maria.contaldo@unicampania.it (M.C.); rosario.serpico@unicampania.it (R.S.); dario.distasio@unicampania.it (D.D.S.)

² Department of Medicine and Surgery, Centre of Neuroscience of Milan, University of Milano-Bicocca, 20126 Milan, Italy; dorina.lauritano@unimib.it

³ Interdisciplinary Department of Medicine, University of Bari “A. Moro”, 70124 Bari, Italy; dellavellaf@gmail.com

* Correspondence: alberta.lucchese@unicampania.it; Tel.: +39-0815667670

† Contributed equally to this article, so they are co-first authors.

Received: 28 August 2020; Accepted: 21 September 2020; Published: 25 September 2020



Abstract: (1) Background: Glycogen storage disease (GSD) represents a group of twenty-three types of metabolic disorders which damage the capacity of body to store glucose classified basing on the enzyme deficiency involved. Affected patients could present some oro-facial alterations: the purpose of this review is to catalog and characterize oral manifestations in these patients. (2) Methods: a systematic review of the literature among different search engines using PICOS criteria has been performed. The studies were included with the following criteria: tissues and anatomical structures of the oral cavity in humans, published in English, and available full text. Review articles and paper published before 1990 were excluded. (3) Results: 757 articles were identified in the initial search. In the end, 45 articles that met the selection criteria has been analyzed. The information extracted from the articles was classified according to the type of GSD (Ia; Ib; II; III; V; XIV). Oral manifestations range from dental caries to severe periodontitis in paediatric patients, from diffuses and recurrent oral ulcers in the cleft lip and palate. (4) Conclusions: Although considered a rare disease, GSD can present a varied number of oral manifestations. Therefore, it is of great importance for the oral medicine specialist to know and classify them.

Keywords: glycogenosis; glycogen storage disease; oral manifestations; oral medicine; review

1. Introduction

Glycogen storage disease (GSD) is a group of rare metabolic diseases, whose overall incidence in the population is estimated at 1 in 2000–43,000. These pathologies are caused by functional deficiency or lack of one of the enzymes that contribute to glycogen metabolism. If the enzyme activity is deficient or not optimal, the glycogen accumulates in the tissues causing alterations and dysfunctions of the organs [1]. Twenty-three types of GSDs are currently recognized, they are classified depending on the organ affected and the enzyme deficiency involved: GSD types 0, I, III, IV, VI, IX, and XI affect the liver; types II, IIIa, V, VII, IXd, X, XII, XIII, and XIV affect the muscles, and type IIA, IIb, and PRKAG2 deficiency cause myopathy/cardiomyopathy [2]. Some GSDs, types III and IXb, can affect both the liver and muscles [3]. It is possible to divide GSDs into two macro-groups, according to the affected organ and therefore to

its symptomatology. The GSDs, caused by a disorder with hepatic-hypoglycemic pathophysiology, present hypoglycemia and hepatomegaly as symptoms. For this reason, the patient must not be at risk of hypoglycaemic crisis through small and frequent meals [4], causing a lowering of the salivary pH, damaging the enamel, and, consequently, favoring the development of dental caries. In the same macro-group of GSDs, particularly in the GSD Ib, neutropenia and neutrophil dysfunction may cause gingival or periodontal diseases and oral ulcers [5]. Moreover, the literature reports that some GSDs with hepatic involvement, such as the GSD I, present oral manifestations such as ulcers, periodontitis, and delay in the eruption of dental elements [6]. Disorders with muscle-energy physiopathology represent the second macro-group of GSDs. Their symptomatology mainly concerns the muscular function, with pains and cramps due to a plasma increase in the muscular enzymes, leading into the chewing muscles' weakness and, consequently, difficulties with mastication function [5]. The purpose of this systematic review is to identify and classify oral manifestations in this group of diseases.

2. Materials and Methods

We performed a systematic review of the literature using different search engines (PubMed, ISI Web of science, and Cochrane Library). The employed MeSH terms were: glycogen storage disease, glycogenesis, oral, mouth, buccal, teeth, tooth, dental, enamel, malocclusion, malocclusions, palate, palatal, tongue, lingual, gum, gums, lip, lips, cheek, cheeks, maxilla, maxillary, mandible, mandibular, craniofacial (Supplementary material—Table S1). Search operations ended in November 2019. The review was performed following the PICOS criteria and PRISMA checklist. The populations of interest were male and female patients, of all ages, with genetically confirmed diagnosis of glycogen storage disease, characterized by alterations of soft and hard tissues of the oral cavity (intervention); comparison was no intervention. Study designs included: comparative studies, cross-sectional studies, retrospective studies, prospective studies, survey studies, case series and case reports. Our aim was to identify and classify oral manifestations in GSD. The included criteria of the examined articles were: presence of manifestations in tissues and anatomical structures of the oral cavity in humans, published in English and available full text. Review and articles published before 1990 were excluded. The selection took place in different steps: after collecting all the initial results, three reviewers (DR, AR, and DDS) read the titles and abstracts, excluded duplicates, and ruled out all those articles that did not meet the inclusion criteria during this initial analysis. Then, two reviewers (AR and DR) read in depth the full texts of the remaining articles, to better evaluate the content. Quality assessment of non-randomized studies will be based on the Risk of Bias in Non-randomized Studies of Interventions (ROBINS I) assessment tool [7]. This tool evaluates seven bias domains and Each one refers the Risk of Bias (RoB) in five grades: low, moderate, serious, critical and no information. The overall evaluation is based on the combination of these seven domains. A study based on a non-randomized design rarely presents a low level of RoB.

The review was submitted and registered on PROSPERO (registration number: CRD42018108049).

3. Results

A total of 757 articles were identified in the initial search. Of those, 345 were duplicates and the other 412 were original articles. Among these, 317 did not match our selection criteria. Reading the full-text version led to the exclusion of further 50 articles. In the end, we identified 45 articles that met our criteria (Figure 1). The PICOS information about the 45 articles and their main contents is summarized in Table 1.

These 45 items, selected by type of GSD found in our research, were divided into 6 groups based on the type of GSD.

Table 1. First author and year of publication, PICOS information and oral manifestation reported in the 45 articles.

#	Author	Study Population	Exposure	Outcome	Study Design	Oral Manifestations
1	Prasad R et al. (2017)	1 (child)	GSD Ib	A Case of Glycogen Storage Disease IB and Giant Cell Tumour of the Mandible	Case report	Giant Cellular Tumour of the mandible;
2	Jones HN et al. (2015)	30 (adults)	GSD II	Quantitative assessment of lingual strength in late-onset Pompe disease.	Retrospective study	Tongue Weakness
3	Fearnotta S et al. (2013)	1 (child)	GSD II	Improvement of dysphagia in a child affected by Pompe disease treated with enzyme replacement therapy.	Case report	Macroglossia
4	Hobson-Webb LD et al. (2013)	3 (adults)	GSD II	Oropharyngeal dysphagia in late-onset Pompe disease, implicating bulbar muscle involvement.	Case series	Tongue Weakness
5	Horvath JJ et al. (2012)	3 (2 adults/1 child)	GSD IIIa	Bulbar muscle weakness and fatty lingual infiltration in glycogen storage disorder type IIIa.	Case series	Tongue Weakness
6	Gift JP et al. (2011)	1 (child)	GSD II	Gingival overgrowth in Pompe disease	Case report	Gingival overgrowth, Malocclusion (3rd class Angle)
7	Dagli AI et al. (2010)	3 (adults)	GSD Ib	Pregnancy in glycogen storage disease type Ib.	Case series	Oral Ulcers
8	Jones HN et al. (2010)	13 (children)	GSD II	Oropharyngeal dysphagia in infants and children with infantile Pompe disease.	Case series	Tongue thrust, oral dysmotility, lip incompetence, and oral disorganization in 3/13 subjects (23%)
9	Amaral Jr et al. (2009)	1 (adult)	GSD Ib	Oral giant cell granuloma in a patient with glycogen storage disease.	Case report	Hypertrophic purplish lesion localized adjacent to the teeth 32, 33 and 34
10	Melis D et al. (2009)	7 (6 adults/1 child)	GSD Ib	Vitamin E supplementation improves neutropenia and reduces the frequency of infections in patients with glycogen storage disease type Ib.	Prospective study	Oral Ulcers
11	Avsar A (2007)	1 (child)	GSD Ia	Dental findings in a child with glycogen storage disease type IA.	Case report	Delayed mixed dentition; tooth decay; taurodontism of both primary and permanent molars
12	Morrellaro C et al. (2005)	1 (child)	GSD Ib	Unusual oral manifestations and evolution in glycogen storage disease type Ib.	Case report	Periodontitis; Oral ulcers
13	Dieckgraefe BK et al. (2002)	36 (children)	GSD Ib	Association of glycogen storage disease Ib and Crohn disease	Retrospective study	9 subjects (25%) had evidence of oral manifestations, including aphthous stomatitis, or periodontitis
14	Kidd SA et al. (2002)	21 (children)	GSD Ia (6); GSD Ib (3); GSD III (12)	Dental disease indices and carries-related microflora in children with glycogen storage disease.	Case series	3 children had carries experience in the primary teeth; 1 carries experience in both the primary and permanent teeth; visible plaque deposits were recorded in all children except one; Gingivitis was present in 62% of the children
15	Kishnani PS et al. (1999)	1 (child)	GSD Ib	Nutritional deficiencies in a patient with glycogen storage disease type Ib.	Case report	Dry lips; Beefy red appearance of the tongue and mucous membranes
16	Dellinger TM et al. (1998)	1 (child)	GSD Ia	Glycogen storage disease and von Willibrand's disease implications for dental treatment: dental management of a pediatric patient.	Case report	multiple carries lesions; High levels of plaque;
17	Katz J et al. (1997)	1 (child)	GSD Ib	Oral manifestations and anesthesia considerations in a child with glycogen storage disease type Ib.	Case report	Oral ulcers; Gingivitis; Delay in eruption time; Hypodontia of primary teeth
18	Thornhill MH (1996)	1 (adult)	GSD V	Masticatory muscle symptoms in a patient with McArdle's disease.	Case report	Tmj dysfunction, masseter and temporal pain.

Table 1. Cont.

#	Author	Study Population	Exposure	Outcome	Study Design	Oral Manifestations
19	Dougherty N et al. (1995)	1 (child)	GSD Ib	Oral sequelae of chronic neutrophil defects in a child with glycogen storage disease type Ib.	Case report	Early bone loss; Early primary tooth loss
20	Salapata Y et al. (1995)	3 (children)	GSD Ib	Oral manifestations in glycogen storage disease type Ib.	Case series	Case 1: Oral ulcer; Geographic tongue. Case 2: Oral ulcers; Gingival recession; Gingival bleeding. Case 3: Narrow palate; Severe recurrent oral ulcers
21	Margolis ML et al. (1994)	1 (adult)	GSD II	Obstructive sleep apnea syndrome in acid malase deficiency.	Case report	Tongue Weakness
22	Baccetti T et al. (1994)	1 (child)	GSD III	Dental and craniofacial findings in a child affected by glycogen storage disease type III.	Case report	Taurodontism of primary dentition; Malocclusion (II class Angle)
23	Wendel U et al. (1993)	1 (adult)	GSD Ib	Glycogen storage disease type Ib: infectious complications and measures for prevention.	Case report	Oral abscesses; Oral ulcers; Periodontitis
24	Barnett AP et al. (1990)	1 (adult)	GSD Ib	Oral complications in type Ib glycogen storage disease.	Case report	Fissure adjacent the right edentulous mandibular alveolar ridge; Browny swelling at the lower bord of the mandible; Traumatic ulceration corresponded to the buccal extension of the lower dentur; Ulceration on the dorsum of the tongue
25	Huie ML et al. (2005)	2 (children)	GSD II	Increased occurrence of cleft lip in glycogen storage disease type II (GSDII).	Case series	1/2 Bilateral severe cleft lip and palate
26	Cleary MA et al. (2002)	2 (children)	GSD III	Facial appearance in glycogen storage disease type III.	Case series	Case 1: Midface hypoplasia; bow-shaped upper lip with a thin vermillion. Case 2: Short philtrum; Midface hypoplasia
27	Pichiecchio A et al. (2017)	9 (children)	GSD II	Muscle MRI of classic infantile pompe patients: Fatty substitution and edema-like changes.	Case series	7 subjects with macroglossia; 6 subjects with tongue weakness
28	Horvath JJ et al. (2015)	22,11 case and 11 control (10 adults/1 child)	GSD II	Correlation between quantitative whole-body muscle magnetic resonance imaging and clinical muscle weakness in Pompe disease.	Case-control study	11 tongue weakness
29	Maggi L et al. (2013)	1 (adult)	GSD II	Familial adult-onset Pompe disease associated with unusual clinical and histological features.	Case report	Tongue Weakness
30	Dubrovsky A et al. (2011)	11 (adults)	GSD II	Expanding the phenotype of late-onset Pompe disease: tongue weakness.	Cross-sectional study	Tongue Weakness
31	Szklamy K et al. (2016)	19 (5 children/14 adults)	GSD II	Analysis of voice quality in patients with late-onset Pompe disease.	Comparative study	9 subjects had an excessive muscle tension of sub-mandibular areas, 2 subjects with short soft palate
32	Wong SY et al. (2016)	27 (18 children/9 adults)	GSD XIV	Defining the Phenotype and Assessing Severity in Phosphoglucomutase-1 Deficiency.	Cross-sectional study	70% cleft palate; 67% bifid uvula
33	Loewenthal N et al. (2015)	7 (5 children/2 adults)	GSD XIV	Phosphoglucomutase-1 deficiency: intrafamilial clinical variability and common secondary adrenal insufficiency.	Retrospective study	1 Pierre-Robin; 3 Cleft palate; 3 Bifid uvula
34	Ondruskova N et al. (2014)	1 (child)	GSD XIV	Glycogen storage disease-like phenotype with central nervous system involvement in a PGMI-CDC patient.	Case report	Cleft palate
35	Bartoli A et al. (2006)	1 (child)	GSD Ib	Glycogen Storage Disease type Ib in a paediatric case.	Case report	Oral candidiasis; Oral ulcers; Gingivitis; Bone defect; Periodontal index 4

Table 1. Cont.

#	Author	Study Population	Exposure	Outcome	Study Design	Oral Manifestations
36	Farrington et al. (1995)	1 (child)	GSD Ib	Effects of cornstarch therapy and other implications of glycogen storage disease on oral hygiene and dentition.	Case report	Oral ulcers; Enamel decalcification; Several posterior teeth had occlusal and interproximal decay; Hard swelling was noted in the left cheek and intraoral redness and swelling noted in the left mucobuccal fold in the area of the maxillary left primary canine and first primary molar
37	Schroeder T et al. (2008)	1 (adult)	GSD Ib	A patient with glycogen storage disease type Ib presenting with acute myeloid leukemia (AML) bearing monosomy 7 and translocation t(3;8)(q26;q24) after 14 years of treatment with granulocyte colony-stimulating factor (G-CSF)	Case report	Aphthous ulcers; Mucosa bleeding
38	Kouwenberg CV et al. (2018)	28 (adult)	GSD V	Mastication and Oral Motor Function in McArdle Disease: Patient Reported Complaints	Survey study	Difficulties with mastication; Cramps in muscles
39	Ma et al. (2018)	1 (child)	GSD Ib	A case of GSD type Ib and its associated oral manifestations with microbial, immunological and histological appearances	Case report	Extensive generalized inflammation of the gingiva, erythema, ulceration, and generalized deep periodontal pocketing with bleeding on probing; severe horizontal bone loss.
40	Martinez et al. (2018)	36 (children)	GSD Ia (22); GSD Ib1 (8); GSD III (2); GSD IXa (3); GSD IXc (1)	Prevalence of feeding difficulties (FDs) and orofacial myofunctional disorders (OMDs)	Cross-sectional study	FDS: 72.2% (26); OMDs: 1 month breathing (12) and oronasal-type breathing (12)
41	Pinto et al. (2017)	1 (adult)	GSD II	Abnormal tongue features	Case report	Tongue weakness with fatty infiltration, diffuse tongue atrophy, normal fatty replacement of the tongue musculature resembling a “tumor-like” structure
42	Duplan et al. (2018)	60 children/adults	GSD Ia (25); GSD Ib (4); GSD III (24); GSD IX (7)	Dental and periodontal manifestations of glycogen storage diseases	Cross-sectional study	Delayed tooth eruption, tooth agenesis, tooth shape abnormalities, severe periodontitis (GSD Ib and neutropenia)
43	Bhattacharya (2004)	2 (children)	GSD Ib	How liver transplantation may lead to clinical improvement in patients with GSD Ib	Case report	Oral ulcers
44	Felice (1995)	2 (adults)	GSD II	Increasing knowledge about clinical features of GSD II (AMID)	Case report	1°: swallowing problems, macroglossia, moderate weakness of the tongue; 2°: no oral features
45	Mil SENDA (2016)	1 (adult)	GSD II	Unusual finding in a patient with GSD II	Case report	Bright tongue (MRI); pseudohypertrophy of the tongue, tumor at right side of atrophic tongue

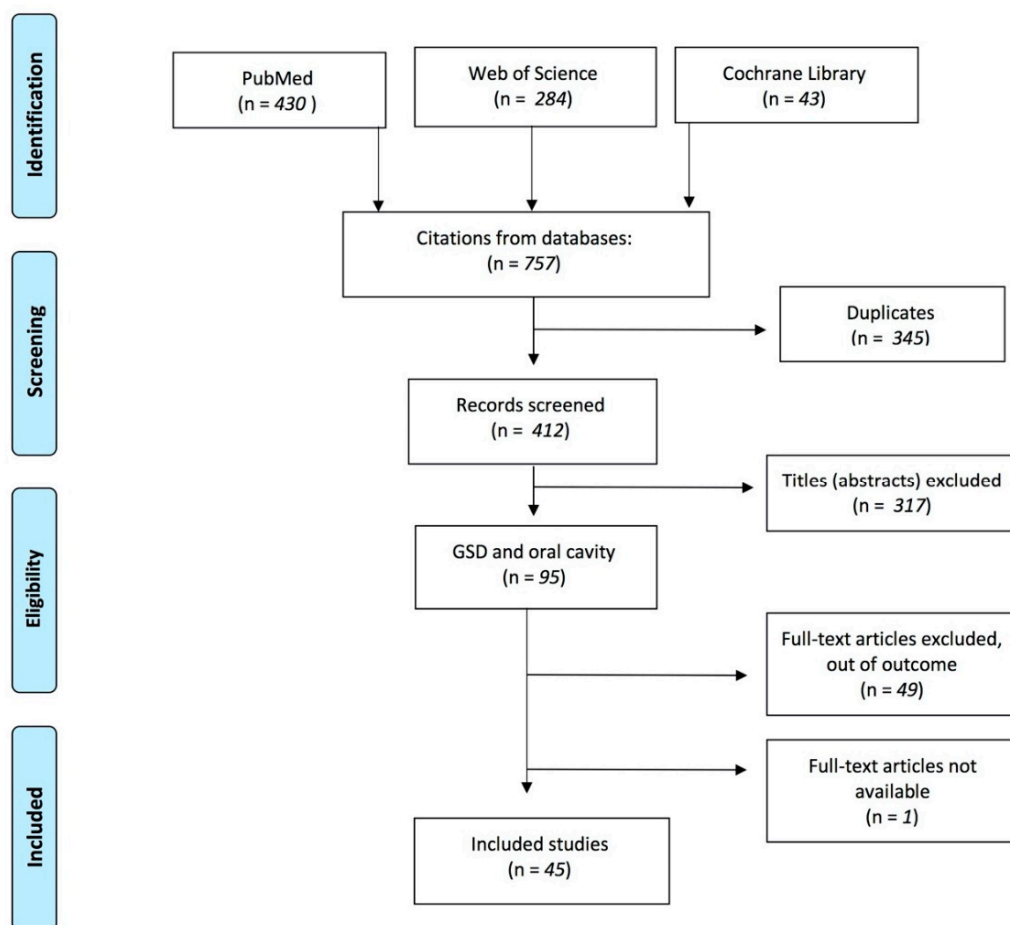


Figure 1. The PRISMA flow diagram summarizes the steps in the selection process.

3.1. Risk of Bias in Individual Studies

Through the evaluation of the 45 analyzed studies, 38 are classified as overall moderate RoB (MR) and 7 as serious overall RoB (SR). In particular, in 40 studies, the recruited patients were volunteers; in 38 studies, the biases due to deviation from the expected intent and in the measurement of the results were found to be MR because the blind was not expected in the study design by the patients, health providers and the outcome assessors. In conclusion, in the analysis of the 45 non-randomized studies, no study appears to have a critical RoB in the individual domain or in the analysis of the overall domain and, therefore, all the studies provide sound evidence (Supplementary Material—Table S2).

3.2. GSD Ia

Three articles [8–10] described oral manifestations in patients with GSD Ia. Avsar [8] describes a single case of a 10-year-old boy who presented a tooth eruption delay, reduced dimensions of the craniofacial complex, taurodontism and multiple caries. Dellinger et al. [9] reported a low level of oral hygiene of the patient with the presence of multiple caries. Duplan et al. [10] evaluated dental and periodontal health in 60 patients with GSD and, among them, 25 had GSD Ia. The mean DMFT of these patients was 2.8, the prevalence of agenesis was 28 percent ($n = 7$) and delayed tooth eruption was observed in 2 patients. Moreover, 10 patients presented tooth shape anomalies (taurodontism, short roots and microdontia) and localized alveolar bone loss was found in 6 patients.

3.3. GSD Ib

Seventeen articles [4,6,10–25] described a correlation between GSD Ib and oral manifestations. Duplan et al. [10], in their study of 60 patients with GSD, examined 4 patients with GSD Ib These

patients had a mean DMFT of 5.5 and all were affected by mild periodontitis. As a result of periodontitis, two patients presented severe alveolar bone loss and one patient a mild generalized alveolar bone loss. In addition, a patient had tooth shape anomalies. Prasad et al. [11], Amaral et al. [12] and Mortellaro et al. [6], in their three case reports articles, described the presence of Giant Cell Tumor (GCT) of the mandible in patients receiving Granulocyte Colony Stimulating Factor (G-CSF). However, it is currently not possible to determine whether there is a cause and effect relationship between G-CSF therapy and the development of GCT in GSD type 1b. Dagli et al. [25] reported the clinical conditions of three patients with GSD Ib in pregnancy: women simply presented oral ulcers during gestation. In a study by Dieckgraefe et al. [13] on the correlation between GSD Ib and IBD, 25 percent of patients (9 out of 36) had oral manifestations such as ulcers or periodontitis. Kishnani et al. [15] reported the presence of dry lips and “beefy red appearance” of the tongue and oral mucosa in a patient with GSD Ib suffering from nutritional deficiency. Wendel et al. [16], Schroeder et al. [17], and Ma et al. [19], in their case reports, described the presence of oral ulcers, gingival bleeding and periodontitis in three patients with GSD Ib. Salapata et al. [20], in their case report on three patients, also reported the presence of oral ulcers, gingival bleeding and periodontitis. Geographic tongue was also present in one patient. Barret et al. [21] reported oral complications in a 22-year-old patient with GSD Ib, on particular a fissure next to the right edentulous mandibular alveolar ridge, a traumatic ulceration both in the buccal extension of the lower denture and on the upper tongue. In 1995, Dougherty et al. [22] presented a case of a pediatric patient with early bone loss resulting in premature loss of dental elements. Bone defects, with a periodontal index of 4, in association with gingival bleeding and the presence of oral ulcers and candidiasis in a nine-year pediatric patient were also described by Bartoli et al. [23]. Three other case reports concerning the oral health of pediatric patients were found in our research. In the first [4], the patient had oral ulcers, gingivitis, delay in eruption time and hypodontia of primary teeth; in the second [24], the patient was affected by oral ulcers, enamel decalcification, tooth decay hard swelling in the left cheek and presence of diffuse oral mucosa inflammation in the area of the maxillary left primary canine and first primary molar. In the last case report [18], the child presented only oral ulcers.

3.4. GSD II

Fifteen articles [5,26–39] related oral manifestations and GSD II. Nine of these articles [5,14,26,27,29,30,33–36,38] described masticatory problems, swallowing problems and lingual weakness. Macroglossia is the second most common manifestation in this type of GSD [29,32,36]. A particular case report was described by Gijt et al. [39], where the patient showed an abnormal gingival overgrowth and Angle’s third-class malocclusion. Huie et al. [28] described the presence of severe and bilateral cleft lip and palate in a patient with GSD II. Milisenda et al. [37], in 2016, described unusual manifestations in a patient with GSD II, such as bright tongue, pseudohypertrophy of the tongue, and tumor on the right side of the atrophic tongue.

3.5. GSD III

The presence of oral manifestations in patients with GSD III is described in three articles [31,40,41]. Baccetti et al. [40] described dental and skeletal atypia in a child with GSD III who presented taurodontism in primary dentition and second-class malocclusion. Cleary et al. [41] described facial appearance in two pediatric patients with GSD III: the first patient was characterized by the presence of a bow-shaped upper lip with a thin vermillion, the second one by a short labial philtrum. Both patients had midface hypoplasia. Horvath et al. [31] described lingual weakness in three patients.

3.6. GSD V

Only two articles included in our study showed the presence of oral manifestations in patients with GSD V. Both articles reported painful symptoms, such as the presence of cramps, and therefore masticatory difficulty in these patients [42,43].

3.7. GSD XIV

We found a correlation between GSD XIV and oral cavity in three studies [44–46]. Wong et al. [44], in a study with 27 patients, described the presence of cleft palate in 19 patients and bifid uvula in other 18 patients. Loewenthal et al. [45], in their study, also described patients with cleft palate and uvula bifida. In addition, one of their patients had Pierre–Robin syndrome. The presence of cleft palate in a patient with GSD XIV is also described by Ondruskova et al. [46].

4. Discussion

GSD Ia is characterized by the deficiency of glucose-6-phosphatase activity. The main clinical manifestation is hypoglycemia, but patients also have high lactatemia, uric acid and triglyceride values. In addition, these patients have growth retardation and hepatomegaly [10]. The frequent intake of carbohydrates, to support blood glucose levels, provides a substrate for oral cariogenic bacteria by implementing the risk of developing caries. Furthermore, the generalized growth retardation of these subjects could also explain the eruption delay of the dental elements [8,9]. GSD Ib is a variant of GSD Ia; it is due to the defect of the glucose-6-phosphate transporter and presents further manifestations, such as neutropenia, altered neutrophil migration and bactericidal activity [16]. Patients are more susceptible to oral ulcers, periodontitis and oral cavity infections [16,19]. Oral hygiene seems to be less effective in patients with GSD; Kidd et al. reported that toothbrushing may be overlooked at night, when the nasogastric tube is inserted for the overnight feeds, and in the morning, because the child needs a carbohydrate intake on waking once the nasogastric tube is removed [47]. In this way, dental prevention needs to be the basis for patients with GSD. Reinforced oral hygiene education, fluoride supplementation, and frequent dental appointments should be necessary to minimize the risk of oral issues and from increased cariogenic exposures [9].

In some reported articles, GSD I is associated with other systemic diseases. In particular, the work of Dieckgraefe et al. [13] found a strong association between GSD Ib and inflammatory bowel disease (IBD). The authors reported several intraoral manifestations that could be related to the IBD, in which the oral presentations are well documented, and therefore cannot be directly attributable to GSD. Kishnani et al. [15] reported the presence of dry lips and “beefy red appearance” of the tongue and oral mucosa in a patient with GSD Ib suffering from nutritional deficiency. In this case, also, the oral manifestations could not be strictly related to the GSD, but rather to the lower serum iron, folate and vitamin B12 levels, caused by the special diet with several restrictions.

GSD III is due to a deficiency of the enzyme amylo-1,6-glucosidase; in this pathology, the most common symptoms are hepatomegaly, hypoglycaemia, recurrent diseases and infections. In addition, these patients are also affected by failure to thrive [48]. Muscle involvement, instead, is more present in GSD IIIa, a subtype of GSD III. According to Baccetti et al. [40], the cranio-facial skeletal anomalies could derive from an incorrect cervico-lumbar posture due to hepatomegaly, together with oral respiration caused by reduced lung expansion. Muscular hypotrophy could also play a decisive role in dysmorphogenesis [41]. GSD II is caused by a deficiency of the acid alpha-1,4-glucosidase enzyme, which leads to an accumulation of glycogen in the muscle tissues. This glycogen storage causes muscle weakness and macroglossia, affecting the chewing and swallowing abilities of patients. Curiously, a single case report reported a massive gingival overgrowth. The authors, even if unable to fully explain the oral manifestation, hypothesized that a mixture of chronic inflammation, dryness of the gingiva, and the slight glycogen accumulation in the fibroblasts might have performed a role in the etiology of the patient’s gingival overgrowth.

The manifestations in patients with GSD V are comparable to those with GSD II. GSD V also affects the muscles and this is due to the deficiency of muscular phosphorylase [43]. Patients show a muscular intolerance syndrome to the effort, associated with myalgia, cramps, fatigue and muscle weakness. GSD XIV is caused by phosphoglucomutase-1 deficiency; manifestations such as cleft palate, bifid uvula and Pierre–Robin syndrome are characteristic of this pathology [45]. The main critical issue of this systematic review is that most of the oral manifestations are not described by dentists, therefore the

different methodological approach to the patient makes the comparison of studies particularly complex. A further problem is that two articles [47,49] describing oral manifestations in patients with different types of GSD did not specify which types of GSD the oral manifestation corresponded to. Patients are more susceptible to oral ulcers, periodontitis and oral cavity infections [16,19]. GSD III is due to a deficiency of the enzyme amylo-1,6-glucosidase; in this pathology, the most common symptoms are hepatomegaly, hypoglycaemia, recurrent diseases and infections. In addition, these patients are also affected by failure to thrive [48]. Muscle involvement, instead, is more present in GSD IIIa, a subtype of GSD III. According to Baccetti et al. [40], the cranio-facial skeletal anomalies could derive from an incorrect cervico-lumbar posture due to hepatomegaly, together with oral respiration caused by reduced lung expansion. Muscular hypotrophy could also play a decisive role in dysmorphogenesis [41]. The manifestations in patients with GSD V are comparable to those with GSD II. GSD V also affects the muscles, and this is due to the deficiency of muscular phosphorylase [43]. Patients show a muscular intolerance syndrome to the effort, associated with myalgia, cramps, fatigue and muscle weakness. GSD XIV is caused by phosphoglucomutase-1 deficiency; manifestations such as cleft palate, bifid uvula and Pierre–Robin syndrome are characteristic of this pathology [45].

Limitations of the Study

The limits regarding this review should be considered. Most of the articles selected were case reports and there is currently no way to validate the quality standard of this type of study. For this reason, we have adapted the ROBINS-I tool [7] to evaluate the quality of the selected case reports. In addition, the inclusion criteria we used in our search strategy enabled us to analyze 45 articles. In vitro, non-English and pre-1990 studies have not been selected. Nonetheless, the exclusion of these papers should be considered as a limitation of this review.

5. Conclusions

Although considered a rare disease, GSDs can present a varied number of oral manifestations. Therefore, it is of great importance for the oral medicine specialist to know and classify them. For example, patients belonging to the macro-group of GSDs with hepatic involvement showed a propensity to develop inflammatory/infectious manifestations of the oral cavity, while patients with GSD muscular problems did not present particular alterations of the oral mucosae or the dental elements. Therefore, the dentist should perform careful management and prevention work in patients with GSD with liver involvement. Further studies should be carried out in order to produce a comparable statistical analysis and increase the quality and quantity of information regarding the oral and dental management of this kind of patients.

Supplementary Materials: The following are available online at <http://www.mdpi.com/2076-3417/10/19/6720/s1>, Table S1: MeSH list used in the search and the combinations used in the search strategy, Table S2: risk of bias assessment for individual studies. Low risk (LR), moderate risk (MR), serious risk (SR), and critical risk (CR) or not interpretable (UR).

Author Contributions: A.R. and D.R. contributed equally to this article, so they are co-first authors. Conceptualization, D.D.S. and R.S.; methodology, A.L.; software, M.C.; validation, F.d.V., A.L. and D.D.S.; formal analysis, D.R.; investigation, A.R.; resources, R.S.; data curation, D.D.S.; writing—original draft preparation, A.R. and D.R.; writing—review and editing, D.L.; visualization, A.L.; supervision, R.S. All authors have read and agreed to the published version of the manuscript.

Funding: This research received no external funding.

Acknowledgments: This research received the grant from the Multidisciplinary Department of Medical-Surgical and Dental Specialties, University of Campania “L. Vanvitelli” funding program VALERE.

Conflicts of Interest: The authors declare no conflict of interest.

References

1. Zhang, X.; Lerman, L.O. The metabolic syndrome and chronic kidney disease. *Transl. Res.* **2017**, *183*, 14–25. [[CrossRef](#)] [[PubMed](#)]

2. Vega, A.I.; Medrano, C.; Navarrete, R.; Desviat, L.R.; Merinero, B.; Rodríguez-Pombo, P.; Vitoria, I.; Ugarte, M.; Pérez-Cerdá, C.; Pérez, B. Molecular diagnosis of glycogen storage disease and disorders with overlapping clinical symptoms by massive parallel sequencing. *Genet. Med.* **2016**, *18*, 1037–1043. [[CrossRef](#)] [[PubMed](#)]
3. Saudubray, J.-M.; Baumgartner, M.R.; Walter, J. *Inborn Metabolic Diseases*; Springer: Berlin/Heidelberg, Germany, 2016.
4. Farrington, F.H.; Duncan, L.L.; Roth, K.S. Looking a gift horse in the mouth: Effects of cornstarch therapy and other implications of glycogen storage disease on oral hygiene and dentition. *Pediatric Dent.* **1995**, *17*, 311–314.
5. Horvath, J.J.; Austin, S.L.; Case, L.E.; Greene, K.B.; Jones, H.N.; Soher, B.J.; Kishnani, P.S.; Bashir, M.R. Correlation between quantitative whole-body muscle magnetic resonance imaging and clinical muscle weakness in pompe disease. *Muscle Nerve* **2015**, *51*, 722–730. [[CrossRef](#)] [[PubMed](#)]
6. Mortellaro, C.; Garagiola, U.; Carbone, V.; Cerutti, F.; Marci, V.; Bonda, P.L.F. Unusual Oral Manifestations and Evolution in Glycogen Storage Disease Type Ib. *J. Craniofacial Surg. Surg.* **2005**, *16*, 45–52. [[CrossRef](#)] [[PubMed](#)]
7. Minozzi, S.; Cinquini, M.; Gianola, S.; Castellini, G.; Gerardi, C.; Banzi, R. Risk of bias in nonrandomized studies of interventions showed low inter-rater reliability and challenges in its application. *J. Clin. Epidemiol.* **2019**, *112*, 28–35. [[CrossRef](#)]
8. Avsar, A. Dental findings in a child with glycogen storage disease type IA. *Quintessence Int.* **2007**, *38*, e36–e40.
9. Inger, T.M.D.; Livingston, H.M.; Holder, R.; Streckfus, C.F. Glycogen storage disease and von Willebrand's disease implications for dental treatment: Dental management of a pediatric patient. *Spec. Care Dent.* **1998**, *18*, 243–246. [[CrossRef](#)]
10. Duplan, M.B.; Hubert, A.; le Norcy, E.; Louzoun, A.; Perry, A.; Chaussain, C.; Labrune, P. Dental and periodontal manifestations of glycogen storage diseases: A case series of 60 patients. *J. Inherit. Metab. Dis.* **2018**, *41*, 947–953. [[CrossRef](#)]
11. Prasad, R.; Estrella, J.; Christodoulou, J.; McKellar, G.; Tchan, M.C. A Third Case of Glycogen Storage Disease IB and Giant Cell Tumour of the Mandible: A Disease Association or Iatrogenic Complication of Therapy. In *JIMD Reports*; Springer: Berlin/Heidelberg, Germany, 2017; Volume 42, pp. 5–8.
12. do Amaral, F.R.; Carvalho, V.M.; Fraga, M.G.; Amaral, T.M.P.; Gomes, C.C.; Gomez, R.S. Oral Giant Cell Granuloma in a Patient with Glycogen Storage Disease. *Open Dent. J.* **2009**, *3*, 144–146. [[CrossRef](#)]
13. Dieckgraefe, B.; Korzenik, J.; Husain, A.; Dieruf, L. Association of glycogen storage disease 1b and Crohn disease: Results of a North American survey. *Eur. J. Pediatrics* **2002**, *161*, S88–S92. [[CrossRef](#)]
14. Jones, H.N.; Muller, C.W.; Lin, M.; Banugaria, S.G.; Case, L.E.; Li, J.S.; O'Grady, G.; Heller, J.H.; Kishnani, P.S. Oropharyngeal dysphagia in infants and children with infantile Pompe disease. *Dysphagia* **2010**, *25*, 277–283. [[CrossRef](#)] [[PubMed](#)]
15. Kishnani, P.S.; Boney, A.; Chen, Y.T. Nutritional deficiencies in a patient with glycogen storage disease type Ib. *J. Inherit. Metab. Dis.* **1999**, *22*, 795–801. [[PubMed](#)]
16. Wendel, U.; Schroten, H.; Burdach, S.; Wahn, V. Glycogen storage disease type Ib: Infectious complications and measures for prevention. *Eur. J. Pediatrics* **1993**, *152*, 49–51. [[CrossRef](#)] [[PubMed](#)]
17. Schroeder, T.; Hildebrandt, B.; Mayatepek, E.; Germing, U.; Haas, R. A patient with glycogen storage disease type Ib presenting with acute myeloid leukemia (AML) bearing monosomy 7 and granulocyte colony-stimulating factor (G-CSF): A case report. *J. Med. Case Rep.* **2008**, *5*, 1–5.
18. Bhattacharya, K.; Heaton, N.; Rela, M.; Walter, J.H.; Lee, P.J. The benefits of liver transplantation in glycogenosis type Ib. *J. Inherit. Metab. Dis.* **2004**, *27*, 539–540. [[CrossRef](#)]
19. Ma, R.; Vaziri, F.M.; Sabino, G.J.; Sarmast, N.D.; Zove, S.M.; Iacono, V.J.; Carrion, J.A. Glycogen storage disease IB and severe periodontal destruction: A case report. *Dent. J.* **2018**, *6*, 53.
20. Salapata, Y.; Laskaris, G.; Drogari, E.; Harokopos, E.; Messaritakis, J. Oral manifestations in glycogen storage disease type 1b. *J. Oral Pathol. Med.* **1995**, *24*, 136–139.
21. Barrett, A.P.; Buckley, D.J.; Katelaris, C.H. Oral complications in type 1B glycogen storage disease. *Oral Surg. Oral Med. Oral Pathol.* **1990**, *69*, 174–176.
22. Dougherty, N.; Gataletto, M.A. Oral sequelae of chronic neutrophil defects: Case report of a child with glycogen storage disease type 1b. *Pediatrics Dent.* **1995**, *17*, 224–229.
23. Bartoli, A.; Bossù, A.; Sfasciotti, G.; Polimeni, A. Glycogen Storage Disease type Ib: A paediatric case report. *Eur. J. Pediatrics Dent.* **2006**, *7*, 192–198.

24. Katz, J. Oral manifestations and anesthesia considerations in a child with glycogen storage disease type 1b: Case report. *Pediatrics Dent.* **1997**, *19*, 123–126.
25. Dagli, A.I.; Lee, P.J.; Correia, C.E.; Rodriguez, C.; Bhattacharya, K.; Steinkrauss, L.; Stanley, C.A.; Weinstein, D.A. Pregnancy in glycogen storage disease type 1b: Gestational care and report of first successful deliveries. *J. Inherit. Metab. Dis.* **2010**, *33*, 151–157. [[CrossRef](#)]
26. Jones, H.N.; Crisp, K.D.; Asrani, P.; Sloane, R.; Kishnani, P.S. Quantitative assessment of lingual strength in late-onset Pompe disease. *Muscle Nerve* **2015**, *51*, 731–735. [[CrossRef](#)] [[PubMed](#)]
27. Margolis, M.L.; Howlett, P.; Goldberg, R.; Eftychiadis, A.; Levine, S. Obstructive Sleep Apnea Syndrome in Acid Maltase Deficiency. *Chest* **1994**, *105*, 947–949. [[CrossRef](#)] [[PubMed](#)]
28. Huie, M.L.; Kasper, J.S.; Arn, P.H.; Greenberg, C.R.; Hirschhorn, R. Increased occurrence of cleft lip in glycogen storage disease type II (GSDII): Exclusion of a contiguous gene syndrome in two patients by presence of intragenic mutations (Am J Med Genet 85: 5-8(1999)). *Am. J. Med. Genet. Part A* **2005**, *137A*, 114.
29. Pichiecchio, A.; Rossi, M.; Cinnante, C.; Colafati, G.S.; de Icco, R.; Parini, R.; Menni, F.; Furlan, F.; Burlina, A.; Sacchini, M.; et al. Muscle MRI of classic infantile pompe patients: Fatty substitution and edema-like changes. *Muscle Nerve* **2017**, *55*, 841–848.
30. Maggi, L.; Salerno, F.; Bragato, C.; Saredi, S.; Blasevich, F.; Maccagnano, E.; Pasanisi, B.; Danesino, C.; Mora, M.; Morandi, L. Familial adult-onset Pompe disease associated with unusual clinical and histological features. *Acta Myol.* **2013**, *32*, 85–90.
31. Horvath, J.J.; Austin, S.L.; Jones, H.N.; Drake, E.J.; Case, L.E.; Soher, B.J.; Bashir, M.R.; Kishnani, P.S. Bulbar muscle weakness and fatty lingual infiltration in glycogen storage disorder type IIIa. *Mol. Genet. Metab.* **2012**, *107*, 496–500.
32. Fecarotta, S.; Ascione, S.; Montefusco, G.; della Casa, R.; Villari, P.; Romano, A.; del Giudice, E.; Andria, G.; Parenti, G. Improvement of dysphagia in a child affected by Pompe disease treated with enzyme replacement therapy. *Ital. J. Pediatrics* **2013**, *39*, 30.
33. Dubrovsky, A.; Corderi, J.; Lin, M.; Kishnani, P.S.; Jones, H.N. Expanding the phenotype of late-onset pompe disease: Tongue weakness: A new clinical observation. *Muscle Nerve* **2011**, *44*, 897–901. [[CrossRef](#)] [[PubMed](#)]
34. Szklanny, K. Analysis of voice quality in patients with late-onset Pompe disease. *Orphanet J. Rare Dis.* **2016**, *11*, 1–9. [[CrossRef](#)] [[PubMed](#)]
35. de Pinto, W.B.V.; de Souza, P.V.S.; Bortholin, T.; Naylor, F.G.M.; Oliveira, A.S.B. Abnormal tongue features as a clinical clue for late-onset Pompe's disease. *Arq. Neuro-Psiquiatria* **2017**, *75*, 835–836. [[CrossRef](#)] [[PubMed](#)]
36. Felice, K.J.; Alessi, A.G.; Grunnet, M.L. Clinical variability in adult-onset acid maltase deficiency: Report of affected sibs and review of the literature. *Medicine* **1995**, *74*, 131–135. [[CrossRef](#)]
37. Milisenda, J.C.; Pujol, T.; Grau, J.M. Not only bright tongue sign in Pompe disease. *Neurology* **2016**, *87*, 1629–1630. [[CrossRef](#)]
38. Hobson-webb, L.D.; Jones, H.N.; Kishnani, P.S. Oropharyngeal dysphagia may occur in late-onset Pompe disease, implicating bulbar muscle involvement. *Neuromuscul. Disord* **2013**, *23*, 319–323. [[CrossRef](#)]
39. de Gijt, J.P.; van Capelle, C.I.; Oosterhuis, J.W.; van der Ploeg, A.T.; van der Wal, K.G.H. Gingival Overgrowth in Pompe Disease: A Case Report. *J. Oral Maxillofac. Surg.* **2011**, *69*, 2186–2190. [[CrossRef](#)]
40. Baccetti, T.; Pierleoni, L.; Filippi, L.; Donati, M.A.; Tollaro, I.; Zammarchi, E. Dental and craniofacial findings in a child affected by glycogen storage disease type III. *J. Clin. Pediatrics Dent.* **1994**, *19*, 55–60.
41. Cleary, M.A.; Walter, J.H.; Kerr, B.A.; Wraith, J.E. Facial appearance in glycogen storage disease type III. *Clin. Dysmorphol.* **2002**, *11*, 117–120. [[CrossRef](#)]
42. Thornhill, M.H. Masticatory muscle symptoms in a patient with McArdle's disease. *Oral Surg. Oral Med. Oral Pathol. Oral Radiol Endodontol.* **1996**, *81*, 544–546. [[CrossRef](#)]
43. Kouwenberg, C.V.; Voermans, N.C.; Quinlivan, R.; van den Engel-Hoek, L. Mastication and Oral Motor Function in McArdle Disease: Patient Reported Complaints. *J. Neuromuscul. Dis.* **2018**, *5*, 353–357. [[CrossRef](#)] [[PubMed](#)]
44. Wong, S.Y.-W.; Beamer, L.J.; Gadowski, T.; Honzik, T.; Mohamed, M.; Wortmann, S.B.; Holmefjord, K.S.B.; Mork, M.; Bowling, F.; Sykut-Cegielska, J.; et al. Defining the Phenotype and Assessing Severity in Phosphoglucomutase-1 Deficiency. *J. Pediatrics* **2016**, *175*, 130–136. [[CrossRef](#)] [[PubMed](#)]
45. Loewenthal, N.; Haim, A.; Parvari, R.; Hershkovitz, E. Phosphoglucomutase-1 deficiency: Intrafamilial clinical variability and common secondary adrenal insufficiency. *Am. J. Med. Genet. Part A* **2015**, *167*, 3139–3143. [[CrossRef](#)] [[PubMed](#)]

46. Nina Ondruskova, H.H.; Honzik, T.; Vondrackova, A.; Tesarova, M.; Zeman, J. Department. Glycogen storage disease-like phenotype with central nervous system involvement in a PGM1-CDG patient Nina. *Neuroendocrinol. Lett* **2014**, *35*, 137–141.
47. Kidd, S.A.; Rademeyer, C.; Roberts, G.J.; Lee, P.J.; Lucas, V.S. Dental disease indices and caries-related microflora in children with glycogen storage disease. *Int. J. Paediatr. Dent.* **2002**, *12*, 8–13. [[PubMed](#)]
48. Kishnani, P.S.; Austin, S.L.; Abdenur, J.E.; Arn, P.; Bali, D.S.; Boney, A.; Chung, W.K.; Dagle, A.I.; Dale, D.; Koeberl, D.; et al. Diagnosis and management of glycogen storage disease type I: A practice guideline of the American College of Medical Genetics and Genomics. *Genet. Med.* **2014**, *16*, 1–29. [[CrossRef](#)]
49. Martinez, C.C.; Tonon, T.; Nalin, T.; Refosco, L.F.; de Souza, C.F.M.; Schwartz, I.V.D. Feeding Difficulties and Orofacial Myofunctional Disorder in Patients with Hepatic Glycogen Storage Diseases. In *JIMD Reports*; Springer: Berlin/Heidelberg, Germany, 2018; Volume 45, pp. 21–27.



© 2020 by the authors. Licensee MDPI, Basel, Switzerland. This article is an open access article distributed under the terms and conditions of the Creative Commons Attribution (CC BY) license (<http://creativecommons.org/licenses/by/4.0/>).