

A NEW SURGICAL AND TECHNICAL APPROACH IN ZYGOMATIC IMPLANTOLOGY

F. GRECCHI¹, A.E. BIANCHI², S. SIERVO², E. GRECCHI¹, D. LAURITANO³, F. CARINCI⁴

¹ Department of Maxillofacial Surgery, Galeazzi Hospital, Milan, Italy

² Department of Maxillofacial Surgery, "Istituto Stomatologico Italiano", Milan, Italy

³ Department of Medicine and Surgery, University of Milano Bicocca, Monza, Italy

⁴ Department of Morphology, Surgery and Experimental Medicine, University of Ferrara, Ferrara, Italy

SUMMARY

Purpose. Different surgical approaches for zygomatic implantology using new designed implants are reported.

Material and methods. The surgical technique is described and two cases reported. The zygomatic fixture has a complete extrasinus path in order to preserve the sinus membrane and to avoid any post-surgical sinus sequelae.

Results. The surgical procedure allows an optimal position of the implant and consequently an ideal emergence of the fixture on the alveolar crest.

Conclusion. The surgical procedures and the zygomatic implant design reduce remarkably the serious post-operative sequelae due to the intrasinus path of the zygomatic fixtures.

Key words: zygomatic implantology, atrophic maxilla, immediate loading.

Introduction

During the last two decades, the placement of zygomatic implants, usually inserted through the maxillary sinus and apically stabilized in the zygomatic bone, has proven to be an effective option in the management of severe atrophic edentulous maxilla (1-4). Zygomatic implants are an useful option in atrophic jaws to avoid bone grafting plus standard implants insertion (5-52, 112-114).

The installation of zygomatic implants was firstly introduced by Brånemark et al. in 1998 in order to rehabilitate the masticatory and the aesthetic functions in severe atrophied maxilla caused by trauma, congenital conditions, tumour resections or increased sinus pneumatization (53). Given the high success rate reported in literature for ZIs placement, this surgical technique can be considered as a valid alternative to bone augmentation and invasive surgery to restore

function and improve the aesthetic result for patients with atrophic edentulous maxilla (2, 53-57). Zygomatic implants, in fact, were subsequently used to rehabilitate severe atrophic upper jaws, classes V and VI, according to Cawood and Howell classification of edentulous jaws (58).

At the beginning 1970 Linkow presented a surgical technique to rehabilitate extremely atrophic maxillae placing smooth implant (diameter 2 mm) apically inserted in the zygomatic bone (59).

New procedures and improvements have been developed since the description of the classical surgical technique in 1998 (53). Stella and Warner introduced the "sinus slot approach" in 2000, a zygomatic implantation method that minimize the presence of the zygomatic implant through the sinus, improving the emergence orientation of the implant, because it allows a more vertical angle of the fixtures than the original technique (60, 115). In 2013 Aparicio (61) et al. proposed a surgical technique based on the rela-

tionship between the zygomatic/alveolar crest complex and the various anatomy guided zygomatic implants pathways (ZAGA) (61).

Extremely absolute contraindications to the placement of zygomatic implants are acute sinus infections, maxillary or zygomatic bone pathologies and underlying uncontrolled or malignant systemic disorders. Relative contraindications are chronic infections of the maxillary sinus and smoking more than 20 cigarettes a day. Zygomatic implants placement in patients that use bisphosphonates is to this day debated. A maxillary sinus with any pathology should preferably be treated before or during surgical procedures (56).

The surgical intervention for zygomatic implant placement, with currently systematic devices offered on the market, results to be remarkably challenging and arduous and it frequently requires the use of general anesthesia. The post surgical sequelae described in the literature (61, 62, 116), such as rhinosinusitis, sinusitis, paresthesia, oroantral fistula, mucositis and perimplant soft tissue dehiscences, represent to this day a critical and significant limit to the implementation of the zygomatic implant surgery and the extensive regular practice of this procedure. The surgical system we present below was first introduced and described by Dr. Balan Igal D.M.D (ISR) and produced by Noris Medical, and it represents an important evolution and improvement of the previous techniques and systems both in the technical-operative procedures and in the eradication of the critical post operative sequelae due to the intrasinus path of the zygomatic fixtures.

Materials and methods

The surgical technique used for zygomatic implants placement considers the use of implant with a specific design: Noris Medical Zygomatic implant has an unthreaded long body ending with a particularly aggressive thread at the apical part of the implant. The zygomatic implant is

anchored in the zygomatic bone with the conical threaded apical segment: the resulting torque, by virtue of the apically threaded 12.5 millimetres, is extremely high. The implant is placed following the procedures of the extramaxillary protocol, which is a successive modification of the traditional Brånemark technique. In the extramaxillary approach a bypass of the maxillary sinus is made in order to prevent any damage to the sinus membrane and to avoid post surgical sinus sequelae. The implant prosthetic platform is therefore shifted buccally to a more appropriate position of the emergence close to the alveolar crest, a less bulky restoration and a better designed prosthesis. A special design of the drills have been made in order to allow the clinician to create a clean and safe tunnel preparation with minimal risk of damaging the membrane. An angled Multi-Unit abutment from 17° to 60° will then provide the correction of the emerging angle needed.

The operative technique we are now describing has the purpose to decrease and avoid post surgical possible complications derived from the sinus path of the zygomatic implant, as rhinitis and sinusitis, difficult and uncomfortable prosthetic restorations consequent to the palatal emergence of the abutments, and extensive problems with the intraoral perimplant soft tissue, as mucositis.

For the surgical approach a slightly incision is made in the maxillary alveolar crest extending from the first molar right region to the left one, paying attention not to injure the emergence of the descending palatine artery that, due to anatomical evolution of the atrophic maxilla, may arise in the alveolar crest.

Two posterior vestibular releasing incisions are made bilaterally considering the emergence of Stensen's duct not to produce any accidental injuries, and a median releasing incision is made below the nasal spine.

Afterward a mucoperiosteal flap is raised simultaneously bilaterally along the whole incision or in two separate stages, according to the different anesthetic approach chosen for the intervention (general anesthesia or deep narcosis).

The mucoperiosteal flap reflection can be performed in two different ways depending on the surgical procedure implicated: the placement of only two zygomatic implants, or a quad-zygomatic surgery.

In the surgical case of two zygomatic implants placement, the mucoperiosteal flap is raised in order to expose the alveolar crest, the anterolateral wall of the maxillary sinus, and the origin of the zygomatic arch where the masseter muscle tendon is inserted; the mucoperiosteal flap of the paranasal region is raised medially to the emergence of the infraorbital nerve.

The infraorbital foramen is the posterior limit of the mucoperiosteal reflection and of the visible bone and it is exceeded only in case of special needs to reach the zygomatic notch and totally expose the outer surface of the malar region, area dedicated to the implant site preparation.

In fact, normally the perception of the bone cutter spill is acquired from the fingertips through the thickness of the overlying skin on the malar bone.

In case of quad-zygoma surgery, the bone region exposed after the mucoperiosteal flap reflection is wider, and it reaches the lower orbital rim. The infraorbital foramen is localized and isolated both medially and distally, the emergence of the infraorbital nerve is meticulously ensured and protected during the entire surgical phases as the anterior zygomatic implant should be positioned at a safe distance from the aforementioned nerve.

The implant site preparation is performed with drills and burs mounted on a contro-angled handpiece. This expedient allows the posterior zygomatic implant positioning distal to the region of the maxillary second premolar easier. The end point of the anterior zygomatic implant will be close to the maxillary canine region bilaterally on the lowermost point of the alveolar crest.

After the mucoperiosteal flap is reflected, the surgical procedure minimum provides one or two corticotomies of the anterolateral wall of the sinus performed with a round diamond bur (4mm in diameter) in order to determine one or

two marking points (Figures 1, 2).

The holes made through the bone with the round diamond bur, in order to set the correct place of the zygomatic implant, are then connected to the intraoral emergence of the zygomatic implant earlier determined using zygomatic burs for groove preparation. These burs have a not working tip and a diamond cylindrical body of three different levels of grit (fine, medium, coarse) (Figure 3).

The conical not working tip of the bur is inserted in the marking point which provides a valid point of support and fulcrum for the subsequent bone preparation in the premolar and in the dis-

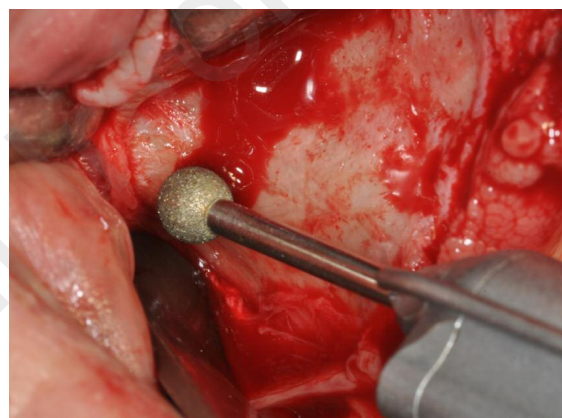


Figure 1
The 4 mm diameter round bur used to determine the initial marking point.

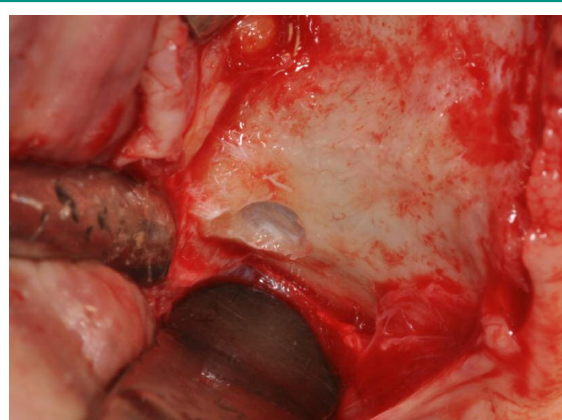


Figure 2
The marking point performed on the sinus wall.

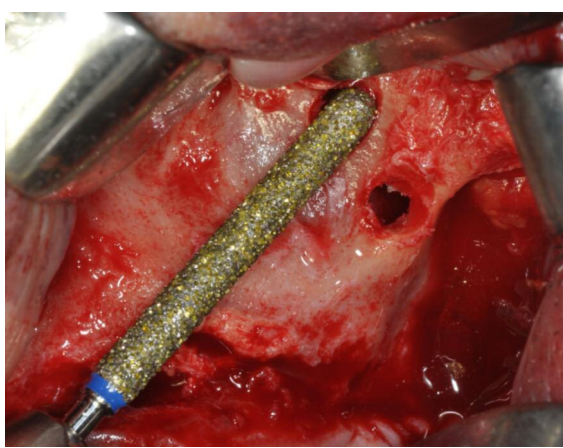


Figure 3
The anterolateral sinus wall is prepared with the coarse zygomatic bur: the not working tip is inserted in the marking point and the working diamond cylindrical body prepares the bone.

tal canine region, passing from the coarser to the finer bur.

The bur will be further deepened with a tangential movement of go and come for two-thirds of its diameter.

This procedure correctly performed respects the integrity of the Schneiderian membrane.

In order not to lacerate the sinus mucosa during following actions, a gentle inward shift of the Schneiderian membrane with a sinus periosteal should be carried out (Figure 4).

Small accidental injuries and lacerations of the sinus mucosa in the region of the zygomatic recess are easily fixed and not significant in terms of sinusitis sequelae; on the contrary, those produced in the region of the alveolar crest, where the end of the zygomatic implant should be, must be solved also using resorbable membranes.

The zygomatic bone preparation, where the apex of the zygomatic implant will be placed and anchored, is performed with a sequence of drills with the final conical cutting tip 2.5 cm long and 2-3.2mm in diameter in apex (Figure 5).

The smooth body of the drill has the same diameter of the antrostomy previously carried out. This slot in the sinus wall reproduces a true apical surgical preparation guide for the drills and it

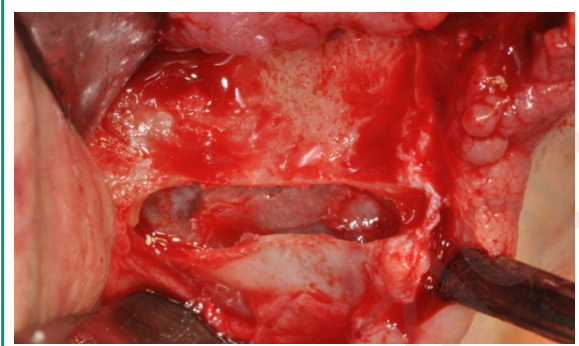


Figure 4
The sinus slot is performed and a gentle inward shift of the Schneiderian membrane is made.

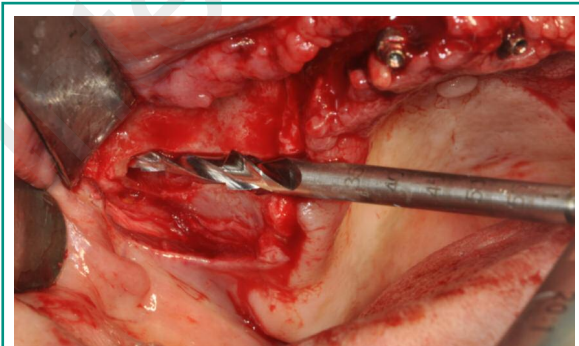


Figure 5
A sequence of drills with the final cutting tip 2.5 cm long and 2-3.2, mm in diameter in apex is used for the zygomatic bone preparation.

prevents dangerous and unsafe errors due to the excessive movements caused by the length of the drills used. It avoids the deviation of the drill from the planned direction.

The first drill must totally penetrate the zygomatic bone and come out through the external cortical layer. It's important to feel with a finger through the skin of the periorbital region the cutting apex of the drill coming out from the zygomatic arch, laterally on the malar bone.

The preparation of the zygomatic implant site continues with the sequence of drills.

A depth indicator is then used to decide the correct length of the zygomatic fixture. The tip of the depth gauge is located on the external corti-

cal zygomatic bone.

The diameter of the final hole on the zygomatic arch carried out by the drills is approximately 2.2 mm in diameter, much lower than the final circumferential size of the implant (3.2 mm). This difference avoids the risk of emergence of the end of the zygoma fixture from the bone during malar screwing when searching primary stability.

Generally we firstly perform the preparation of the anterior zygomatic implant, which is the more complicated and dangerous one, and subsequently we complete the preparation of the distal fixture tilting the drills in relation to the residual bone available, the most posterior and vertical as possible, so that the apexes are convergent, but do not interfere between them.

The implant is positioned with an extraoral screwdriver, if the anatomy is favourable, or with the usual operations of screwing that we use in all types of endosseous implants (Figure 6).

The emergence of the fixture must be in the optimal site from a prosthetic point of view, on the alveolar crest. The angled abutment position is checked in order to obtain an ideal emergence of the prosthetic abutment, and it's screwed.

The coverage of the region with Bichat fat pad or resorbable membranes is performed in those cases that present particular conditions of vestibular maxillary concavity and therefore it is not usually and frequently carried out (Figure 7).

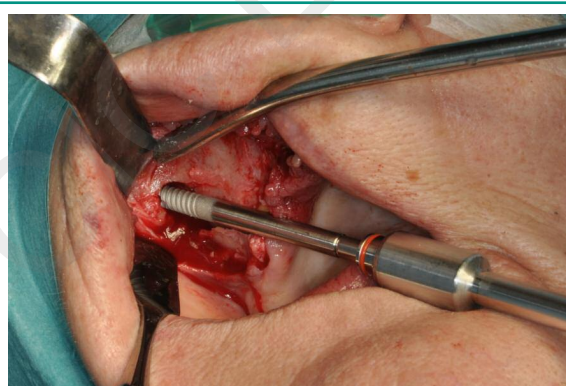


Figure 6
The zygomatic implant is positioned with an extraoral screwdriver.

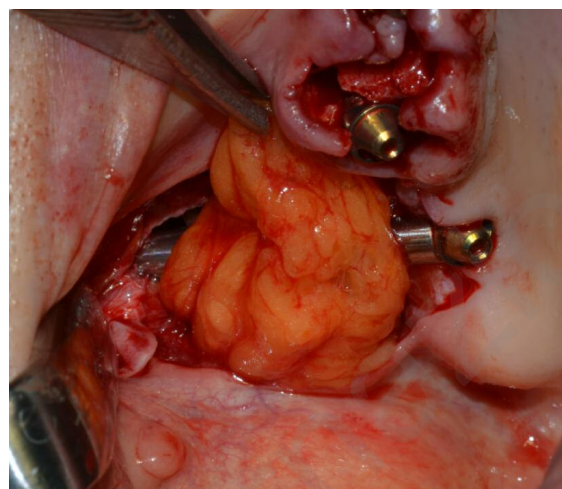


Figure 7
The Bichat fat pad used to cover the zygomatic implant.

The resorbable suture completes the surgical intervention.

Clinical case 1

A 59-year-old Caucasian male patient with partial edentulous maxilla required a fixed prosthetic rehabilitation with zygomatic implants. He had no history of pathologies that could contraindicate surgery.

Panoramic radiography and CT were examined to evaluate the bone volume of the maxilla and of the zygomas and to eliminate the risk of undiagnosed pathologies.

The surgery procedures were performed under general anesthesia with endotracheal intubation reinforced with local infiltration of anesthesia with vasoconstrictor. Three upper incisors were extracted and two zygomatic implants and four normal implants were placed (Figure 8).

Clinical case 2

A 51-year-old Caucasian female patient with total edentulous maxilla needed prosthetic rehabil-

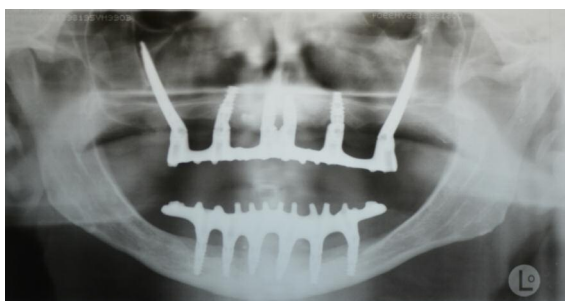

Figure 8
Post surgery orthopantomograms of clinical case 1.

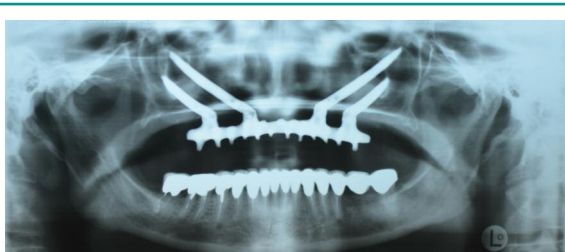


Figure 9
Post surgery radiographic examination of clinical case 2.

itation. The patient refused grafting procedures prior to implant placement, as onlay bone grafting and/or sinus lift. It was decided to perform a quad-zygoma implant rehabilitation.

Pre op. radiographic examination, included orthopantomograms and computed tomography, were evaluated. An advanced vertical and horizontal bone loss of the alveolar ridge was revealed and there was no evidence of other pathologies that could exclude surgery.

The operation was executed under general anesthesia with nasotracheal intubation and local injection of anesthesia with vasoconstrictor. Four zygomatic implants were placed (Figure 9).

Discussion

A functional occlusal prosthetic rehabilitation of severely resorbed edentulous maxilla with conventional implant-supported dental bridges

constitutes a difficult therapeutic challenge. Tooth extractions, use of dentures and the presence of extensive maxillary sinus often result in a lack of bone volume. Therefore there are many obstacles and limitations to the final result that can be achieved using bone-anchored fixed prostheses in all those patients with advanced atrophic maxilla. Recurrently the residual alveolar bone is too small for placement and osseointegration of dental implants (63). For more than three decades, bone grafting prior to, or simultaneously with, implant placement, has become routine in oral rehabilitation. Several bone augmentation techniques (maxillary sinus floor augmentation, onlay bone grafting...) have been described in literature with the common goal of increasing the volume of the residual bone in order to place implants and rehabilitate the masticatory function and speech with fixed prosthesis (54, 64-67). However all bone grafting procedures are resource demanding and require long treatment and healing periods, such as Le Fort I osteotomies or revascularized flaps. High risk for morbidity is present because of harvesting of bone grafts, and the failure rates are more than in nongrafted situations (68). Many efforts have been made to pursue alternatives to major bone grafting procedures and to achieve a valid osseointegrated implant anchorage exploiting the residual native bone. The need of bone grafting may be replaced and bypassed by the use of remaining existing anchorage bone sites in the maxillary tuberosities, pterygoid plates or zygomatic bone. Some Authors suggested the pterigomaxillary suture as an alternative location for implant placement, but the risk of vascular damage is very high because of the path of the descending maxillary artery (69-71). Other Authors proposed the use of tilted implants and/or short implants to use the residual bone and to avoid any sinus lift procedures (64).

Brånemark et al. firstly introduced the use of zygomatic bone for anchorage of zygomatic fixtures (53). This surgical technique was presented for rehabilitating patients with extremely resorbed maxilla and wide-ranging maxillary

defects due to tumor resections, congenital defects, traumatic events. The use of zygomatic implants reduced the time of treatment and the number of surgical operations. The surgical approach consists of a similar Le Fort I vestibular incision between the first molar region with vertical releasing incisions. Subsequently a mucoperiosteal flap is raised in order to expose the hard palate and the alveolar crest, the zygomatic complex, the lateral wall of the maxillary sinus, the infraorbital nerve. A bone window is opened at the uppermost lateral aspect of the maxillary sinus wall and the sinus membrane is prudently reflected in the sinus cavity. The site for the implant placement in the maxillary sinus and on the palatal side of the alveolar crest is then prepared with a series of drills. Unfortunately this surgical procedure often causes problems related to the intrasinus path of the zygomatic implant and patient discomfort and difficulties with hygiene procedures and speech due to the bulky dental bridge at the palatal aspect.

Since Brånemark, new procedures and improvements have been made.

In 2000 Stella and Warner (60) introduced “the sinus slot approach”. This operative technique allows a more vertical placement of the zygomatic implant and consequently a better buccal emergence of the implant. The crestal incision is less extensive than that of Brånemark: it’s made from one tuberosity to the contralateral one, vertical releasing incisions are made. The raising of the mucoperiosteal flap allows a good visibility of the region and the palatal mucosa is reflected only to expose the alveolar ridge. Two bur holes are made, the first on the superior extent of the contour of the zygomatic buttress, and the second one on the alveolar ridge. Afterward a slot connects the holes and it results in a small anastomy in order to have a correct orientation of the drills used for zygomatic implants placement. The sinus mucosa is preserved and the implant can be directly seen during all the surgical procedures. A greater bone to implant contact is obtained. The presence of the zygomatic implant through the si-

nus is minimize and postoperative edema and ecchymosis are reduced. The patient discomfort decreases because of the improvements of the implant emergence, which results more buccally than the original technique.

Aparicio (61) et al. in 2013 proposed a more anatomically and more prosthetically driven approach called “the zygomatic anatomy guided approach” (ZAGA). This surgical technique focuses on interindividual anatomical differences between patients. No initial window or slot is needed to be prepared on the lateral wall of the maxillary sinus because the preparation of the zygomatic implant site is guided by the anatomy of the edentulous maxilla. The procedure, in order to determine the placement of the fixture, is different from the previously described techniques. Firstly, the correct emergence of the zygomatic implant on the alveolar ridge is established in order to obtain an optimal prosthetic outcome. Then, the apical entrance of the implant in the zygomatic bone is decided according to the number and to the length of implants required, and to the anatomy of the area. Thirdly, the implant pathway is identified after connecting the two points: the direction of the final preparation of the site is guided. The final path of the implant body may definitely depends on the anatomy of the patient, and it may vary from a totally intrasinus placement to a totally extrasinus one.

The surgical technique we have above described introduces new expedients and precautions in order to decrease and avoid post-surgical possible complications. The innovative design of the zygomatic implant is different from the first proposed and used by other Authors: the implant has an unthreaded long body ending with a particularly aggressive threaded apical segment. The risk of peri-implantitis is so decreased that is of paramount importance in two-stage implantology (13, 14, 16, 72-111, 117).

The zygomatic fixture has a complete extrasinus path in order to preserve the sinus membrane and to avoid any post-surgical sinus sequelae. The surgical procedure allows an optimal position of the implant and consequently

an ideal emergence of the fixture on the alveolar crest. The correction of the emerging angle needed is provided thanks to angled Multi Unit Abutments from 17 to 60°.

Those developments and improvements both of the surgical procedures and the zygomatic implant design reduce the serious post-operative sequelae remarkably due to the intrasinus path of the zygomatic fixtures.

Acknowledgments

The Authors thank Dr. Balan Igal D.M.D (ISR) and Noris Medical.

References

1. Malevez C, Daelemans P, Adriaenssens P, et al. Use of zygomatic implants to deal with resorbed posterior maxillae. *Periodontol* 2000. 2003;33:82-89.
2. Branemark PI, Grondahl K, Ohnrell LO, et al. Zygoma fixture in the management of advanced atrophy of the maxilla: technique and long-term results. *Scand J Plast Reconstr Surg Hand Surg*. 2004;38:70-85.
3. Parel SM, Branemark PI, Ohnrell LO, et al. Remote implant anchorage for the rehabilitation of maxillary defects. *J Prosthet Dent*. 2001;86:377-381.
4. Higuchi KW. Minimization in oral implant rehabilitation: a patient-centered ethics-based approach in zygomatic implants. In: eds. Aparicio C. *The anatomy guided approach*. Berlin: Quintessence; 2012:1-6.
5. Lucchese A, Carinci F, Saggese V, et al. Immediate loading versus traditional approach in functional implantology. *European Journal of Inflammation*. 2012; 10:55-58.
6. Traini T, Danza M, Zollino I, et al. Histomorphometric evaluation of an immediately loaded implant retrieved from human mandible after 2 years. *International Journal of Immunopathology and Pharmacology*. 2011;24:31-36.
7. Scarano A, Murmura G, Carinci F, et al. Immediately loaded small-diameter dental implants: evaluation of retention, stability and comfort for the edentulous patient. *European Journal of Inflammation*. 2012;10:19-23.
8. Degidi M, Piattelli A, Carinci F. Clinical outcome of narrow diameter implants: a retrospective study of 510 implants. *J Periodontol*. 2008;79:49-54.
9. Degidi M, Piattelli A, Iezzi G, et al. Do longer implants improve clinical outcome in immediate loading? *Int J Oral Maxillofac Surg*. 2007;36:1172-1176.
10. Degidi M, Piattelli A, Carinci F. Immediate loaded dental implants: comparison between fixtures inserted in postextractive and healed bone sites. *J Craniofac Surg*. 2007;18:965-971.
11. Degidi M, Piattelli A, Iezzi G, et al. Retrospective study of 200 immediately loaded implants retaining 50 mandibular overdentures. *Quintessence Int*. 2007;38: 281-288.
12. Degidi M, Piattelli A, Iezzi G, et al. Immediately loaded short implants: analysis of a case series of 133 implants. *Quintessence Int*. 2007;38:193-201.
13. Degidi M, Piattelli A, Iezzi G, et al. Wide-diameter implants: Analysis of clinical outcome of 304 fixtures. *Journal of Periodontology*. 2007;78:52-58.
14. Degidi M, Piattelli A, Gehrke P, et al. Five-year outcome of 111 immediate nonfunctional single restorations. *J Oral Implantol*. 2006;32:277-285.
15. Degidi M, Piattelli A & Carinci F. Parallel screw cylinder implants: Comparative analysis between immediate loading and two-stage healing of 1005 dental implants with a 2-year follow up. *Clinical Implant Dentistry and Related Research*. 2006;8:151-160.
16. Degidi M, Piattelli A, Gehrke P, et al. Clinical outcome of 802 immediately loaded 2-stage submerged implants with a new grit-blasted and acid-etched surface: 12-month follow-up. *Int J Oral Maxillofac Implants*. 2006;21:763-768.
17. Degidi M, Piattelli A, Felice P, et al. Immediate functional loading of edentulous maxilla: a 5-year retrospective study of 388 titanium implants. *J Periodontol*. 2005;76:1016-1024.
18. Rigo L, Viscioni A, Franco M, et al. Overdentures on implants placed in bone augmented with fresh frozen bone. *Minerva Stomatol*. 2011;60:5-14.
19. Carinci F, Brunelli G, Franco M, et al. A retrospective study on 287 implants installed in resorbed maxillae grafted with fresh frozen allogeneous bone. *Clin Implant Dent Relat Res*. 2010;12:91-98.
20. Viscioni A, Rigo L, Franco M, et al. Reconstruction of severely atrophic jaws using homografts and simultaneous implant placement: a retrospective study. *J Oral Implantol*. 2010;36:131-139.
21. Franco M, Rigo L, Viscione A, et al. CaPO4 blasted implants inserted into iliac crest homologue frozen grafts. *The Journal of oral implantology*. 2009;35:176-180.
22. Viscioni A, Franco M, Rigo L, et al. Implants inserted into homografts bearing fixed restorations. *Int J Prosthodont*. 2009;22:148-154.
23. Franco M, Viscioni A, Rigo L, et al. Clinical outcome of narrow diameter implants inserted into allografts. *J Appl Oral Sci*. 2009;17:301-306.
24. Viscioni A, Franco M, Rigo L, et al. Retrospective study of standard-diameter implants inserted into allografts. *J Oral Maxillofac Surg*. 2009;67:387-393.
25. Baj A, Sollazzo V, Lauritano D, et al. Lights and shadows of bone augmentation in severe resorbed mandible

- in combination with implant dentistry. *Journal of biological regulators and homeostatic agents*. 2016;30(2 Suppl 1):177-182.
26. Carinci F, Brunelli G, Zollino I, et al. Mandibles grafted with fresh-frozen bone: an evaluation of implant outcome. *Implant Dent*. 2009;18:86-95.
 27. Franco M, Tropina E, De Santis B, et al. A 2-year follow-up study on standard length implants inserted into alveolar bone sites augmented with homografts. *Stomatologija*. 2008;10:127-132.
 28. Danza M, Paracchini L, Carinci F. Tridimensional finite element analysis to detect stress distribution in implants. *Dental Cadmos*. 2012;80:598-602.
 29. Danza M, Grecchi F, Zollino I, et al. Spiral implants bearing full-arch rehabilitation: Analysis of clinical outcome. *Journal of Oral Implantology*. 2011;37:447-455.
 30. Danza M, Zollino I, Avantiaggiato A, et al. Distance between implants has a potential impact of crestal bone resorption. *Saudi Dental Journal*. 2011;23:129-133.
 31. Carinci F & Danza M. Clinical outcome of implants inserted in piezo split alveolar ridges: A pilot study. In: *Perspectives on Clinical Dentistry*. 2011:29-30.
 32. Danza M, Zollino I, Guidi R, et al. Computer planned implantology: Analysis of a case series. In: *Perspectives on Clinical Dentistry*. 2011:287-300.
 33. Danza M, Carinci F. Flapless surgery and immediately loaded implants: a retrospective comparison between implantation with and without computer-assisted planned surgical stent. *Stomatologija*. 2010;12:35-41.
 34. Danza M, Quaranta A, Carinci F, et al. Biomechanical evaluation of dental implants in D1 and D4 bone by Finite Element Analysis. *Minerva stomatologica*. 2010;59:305-313.
 35. Danza M, Riccardo G, Carinci F. Bone platform switching: a retrospective study on the slope of reverse conical neck. *Quintessence Int*. 2010;41:35-40.
 36. Danza M, Fromovich O, Guidi R, et al. The clinical outcomes of 234 spiral family implants. *J Contemp Dent Pract*. 2009;10:E049-056.
 37. Calvo-Guirado JL, Ortiz-Ruiz AJ, Lopez-Mari L, et al. Immediate maxillary restoration of single-tooth implants using platform switching for crestal bone preservation: a 12-month study. *Int J Oral Maxillofac Implants*. 2009;24:275-281.
 38. Danza M, Guidi R, Carinci F. Comparison Between Implants Inserted Into Piezo Split and Unsplit Alveolar Crests. *Journal of Oral and Maxillofacial Surgery*. 2009;67:2460-2465.
 39. Danza M, Scarano A, Zollino I, et al. Evaluation of biological width around implants inserted in native alveolar crest bone. *Journal of Osseointegration*. 2009;1:73-76.
 40. Danza M, Zollino I, Guidi R, et al. A new device for impression transfer for non-parallel endosseous implants. *Saudi Dental Journal*. 2009;21:79-81.
 41. Andreasi Bassi M, Lopez MA, Confalone L, et al. Clinical outcome of a two-piece implant system with an internal hexagonal connection: a prospective study. *J Biol Regul Homeost Agents*. 2016;30:7-12.
 42. Danza M, Guidi R, Carinci F. Spiral family implants inserted in postextraction bone sites. *Implant Dent*. 2009;18:270-278.
 43. Falisi G, Severino M, Rastelli C, et al. The effects of surgical preparation techniques and implant macrogeometry on primary stability: An in vitro study. *Medicina Oral, Patologia Oral y Cirugia Bucal*. 2017;22:e201-e206.
 44. Pocaterra A, Caruso S, Bernardi S, et al. Effectiveness of platelet-rich plasma as an adjunctive material to bone graft: a systematic review and meta-analysis of randomized controlled clinical trials. *International Journal of Oral and Maxillofacial Surgery*. 2016;45:1027-1034.
 45. Marrelli M, Pujia A, Palmieri F, et al. Innovative approach for the in vitro research on biomedical scaffolds designed and customized with CAD-CAM technology. *International Journal of Immunopathology and Pharmacology*. 2016;29:778-783.
 46. Giuca MR, Pasini M, Giuca G, et al. Investigation of periodontal status in type 1 diabetic adolescents. *European journal of paediatric dentistry : official journal of European Academy of Paediatric Dentistry*. 2015;16:319-323.
 47. Giuca MR, Pasini M, Caruso S, et al. Index of orthodontic treatment need in obese adolescents. *International Journal of Dentistry*. 2015;2015:
 48. Caruso S, Sgolastra F, Gatto R. Dental pulp regeneration in paediatric dentistry: The role of stem cells. *European Journal of Paediatric Dentistry*. 2014;15:90-94.
 49. De Vico G, Ottria L, Bollero P, et al. Aesthetic and functionality in fixed prosthodontic: experimental and clinical analysis of the CAD-CAM systematic 3Shape. *Oral Implantol (Rome)*. 2008;1:104-115.
 50. Moretto D, Gargari M, Nordsjo E, et al. Immediate loading: a new implant technique with immediate loading and aesthetics: Nobel Active. *Oral Implantol (Rome)*. 2008;1:50-55.
 51. Spinelli D, De Vico G, Condò R, et al. Transcrestal guided sinus lift without grafting materials: A 36 months clinical prospective study. *ORAL and Implantology*. 2015;8:74-86.
 52. Bartuli FN, Luciani F, Caddeo F, et al. Piezosurgery vs High Speed Rotary Handpiece: a comparison between the two techniques in the impacted third molar surgery. *Oral Implantol (Rome)*. 2013;6:5-10.
 53. Branemark PI. Surgery and fixture installation: zygomaticus fixture clinical procedures. Place: Nobel Biocare AB, 1998.
 54. Aparicio C, Manresa C, Francisco K, et al. The long-term use of zygomatic implants: a 10-year clinical and radiographic report. *Clin Implant Dent Relat Res*. 2014;16:447-459.
 55. Penarrocha M, Garcia B, Marti E, et al. Rehabilitation

- of severely atrophic maxillae with fixed implant-supported prostheses using zygomatic implants placed using the sinus slot technique: clinical report on a series of 21 patients. *Int J Oral Maxillofac Implants.* 2007;22:645-650.
56. Chrcanovic BR, Albrektsson T & Wennerberg A. Survival and Complications of Zygomatic Implants: An Updated Systematic Review. *J Oral Maxillofac Surg.* 2016;74:1949-1964.
 57. Grecchi F, Busato A, Grecchi E, et al. Surgically-guided zygomatic and pterygoid implants - a no-grafting rehabilitation approach in severe atrophic maxilla -A case report. 2013;1.
 58. Cawood JI, Howell RA. A classification of the edentulous jaws. *Int J Oral Maxillofac Surg.* 1988;17:232-236.
 59. Linkow LI, Cherchève R. Theories and techniques of oral implantology. Place: C. V. Mosby Co, 1970.
 60. Stella JP, Warner MR. Sinus slot technique for simplification and improved orientation of zygomatic dental implants: a technical note. *Int J Oral Maxillofac Implants.* 2000;15:889-893.
 61. Aparicio C, Manresa C, Francisco K, et al. Zygomatic implants placed using the zygomatic anatomy-guided approach versus the classical technique: a proposed system to report rhinosinusitis diagnosis. *Clin Implant Dent Relat Res.* 2014;16:627-642.
 62. Davo R. Sinus reactions to zygomatic implants. In: (ed. (eds. Aparicio, C). *The anatomy guided approach.* Berlin: Quintessence; 2012:59-76.
 63. Stievenart M, Malevez C. Rehabilitation of totally atrophied maxilla by means of four zygomatic implants and fixed prosthesis: a 6-40-month follow-up. *Int J Oral Maxillofac Surg.* 2010;39:358-363.
 64. Aparicio C, Manresa C, Francisco K, et al. Zygomatic implants: indications, techniques and outcomes, and the zygomatic success code. *Periodontol 2000.* 2014;66:41-58.
 65. Becktor JP, Hallstrom H, Isaksson S, et al. The use of particulate bone grafts from the mandible for maxillary sinus floor augmentation before placement of surface-modified implants: results from bone grafting to delivery of the final fixed prosthesis. *J Oral Maxillofac Surg.* 2008;66:780-786.
 66. Nystrom E, Nilson H, Gunne J, et al. Reconstruction of the atrophic maxilla with interpositional bone grafting/Le Fort I osteotomy and endosteal implants: a 11-16 year follow-up. *Int J Oral Maxillofac Surg.* 2009;38:1-6.
 67. Hallman M, Hedin M, Sennerby L, et al. A prospective 1-year clinical and radiographic study of implants placed after maxillary sinus floor augmentation with bovine hydroxyapatite and autogenous bone. *J Oral Maxillofac Surg.* 2002;60:277-284; discussion 285-276.
 68. Esposito M, Hirsch JM, Lekholm U, et al. Biological factors contributing to failures of osseointegrated oral implants. (I). Success criteria and epidemiology. *Eur J Oral Sci.* 1998;106:527-551.
 69. Fernandez Valeron J, Fernandez Velazquez J. Placement of screw-type implants in the pterygomaxillary-pyramidal region: surgical procedure and preliminary results. *Int J Oral Maxillofac Implants.* 1997;12:814-819.
 70. Graves SL. The pterygoid plate implant: a solution for restoring the posterior maxilla. *Int J Periodontics Restorative Dent.* 1994;14:512-523.
 71. Tulasne JF. Osseointegrated fixtures in the pterygoid region. In: eds. Worthington P, Branemark PL. *An advanced osseointegration surgery: applications in the maxillofacial region.* Chicago, IL: Quintessence; 1992:182-188.
 72. Lauritano D, Martinelli M, Mucchi D, et al. Bacterial load of periodontal pathogens among Italian patients with chronic periodontitis: A comparative study of three different areas. *Journal of Biological Regulators and Homeostatic Agents.* 2016;30:149-154.
 73. Lauritano D, Scapoli L, Mucchi D, et al. Infectogenomics: Lack of association between vdr, il6, il10 polymorphisms and "red Complex" bacterial load in a group of Italian adults with chronic periodontal disease. *Journal of Biological Regulators and Homeostatic Agents.* 2016;30:155-160.
 74. Checchi L, Gatto MR, Checchi V, et al. Bacteria prevalence in a large Italian population sample: A clinical and microbiological study. *Journal of Biological Regulators and Homeostatic Agents.* 2016;30:199-208.
 75. Meynardi F, Pasqualini ME, Rossi F, et al. Correlation between dysfunctional occlusion and periodontal bacterial profile. *J Biol Regul Homeost Agents.* 2016;30:115-121.
 76. Lombardo L, Carinci F, Martini M, et al. Quantitative evaluation of dentin sialoprotein (DSP) using microbeads - A potential early marker of root resorption. *ORAL and Implantology.* 2016;9:132-142.
 77. Lauritano D, Cura F, Candotto V, et al. Evaluation of the Efficacy of Titanium Dioxide with Monovalent Silver Ions Covalently Linked (Tiab) as an Adjunct to Scaling and Root Planing in the Management of Chronic Periodontitis Using Pcr Analysis: A Microbiological Study. *J Biol Regul Homeost Agents.* 2015;29:127-130.
 78. Scapoli L, Girardi A, Palmieri A, et al. Quantitative Analysis of Periodontal Pathogens in Periodontitis and Gingivitis. *J Biol Regul Homeost Agents.* 2015;29:101-110.
 79. Lauritano D, Cura F, Candotto V, et al. Periodontal Pockets as a Reservoir of Helicobacter Pylori Causing Relapse of Gastric Ulcer: A Review of the Literature. *J Biol Regul Homeost Agents.* 2015;29:123-126.
 80. Scapoli L, Girardi A, Palmieri A, et al. Interleukin-6 Gene Polymorphism Modulates the Risk of Periodontal Diseases. *J Biol Regul Homeost Agents.* 2015;29:111-116.

81. Carinci F, Girardi A, Palmieri A, et al. LAB®-Test 1: Peri-Implantitis and bacteriological analysis. *European Journal of Inflammation*. 2012;10:91-93.
82. Carinci F, Girardi A, Palmieri A, et al. LAB®-test 2: Microflora and periodontal disease. *European Journal of Inflammation*. 2012;10:95-98.
83. Carinci F, Girardi A, Palmieri A, et al. Lab®-test 3: Genetic susceptibility in periodontal disease. *European Journal of Inflammation*. 2012;10:99-101.
84. Scapoli L, Girardi A, Palmieri A, et al. IL6 and IL10 are genetic susceptibility factors of periodontal disease. *Dent Res J (Isfahan)*. 2012;9:S197-201.
85. Carinci F, Girardi A, Palmieri A, et al. Lab-test 2: microflora and periodontal disease. *European Journal of Inflammation*. 2012;10:95-98.
86. Cura F, Palmieri A, Girardi A, et al. Lab-Test (R) 4: Dental caries and bacteriological analysis. *Dent Res J (Isfahan)*. 2012;9:S139-141.
87. Roncati M, Lauritano D, Cura F, et al. Evaluation of light-emitting diode (led-835 nm) application over human gingival fibroblast: An in vitro study. *Journal of Biological Regulators and Homeostatic Agents*. 2016;30:161-167.
88. Caccianiga G, Rey G, Paiusco A, et al. Oxygen high level laser therapy is efficient in treatment of chronic periodontitis: A clinical and microbiological study using PCR analysis. *Journal of Biological Regulators and Homeostatic Agents*. 2016;30:87-97.
89. Lauritano D, Bignozzi CA, Pazzi D, et al. Evaluation of the efficacy of a new oral gel as an adjunct to home oral hygiene in the management of chronic periodontitis. A microbiological study using PCR analysis. *J Biol Regul Homeost Agents*. 2016;30:123-128.
90. Carinci F, Palmieri A, Girardi A, et al. Aquolab® ozone-therapy is an efficient adjuvant in the treatment of chronic periodontitis: A case-control study. *Journal of Orofacial Sciences*. 2015;7:27-32.
91. Lauritano D, Cura F, Gaudio RM, et al. Polymerase Chain Reaction to Evaluate the Efficacy of Silica Dioxide Colloidal Solutions in the Treatment of Chronic Periodontitis: A Case Control Study. *J Biol Regul Homeost Agents*. 2015;29:131-135.
92. Lauritano D, Petruzzi M, Nardi GM, et al. Single Application of a Dessicating Agent in the Treatment of Recurrent Aphthous Stomatitis. *J Biol Regul Homeost Agents*. 2015;29:59-66.
93. Carinci F, Lauritano D, Cura F, et al. Prevention of bacterial leakage at implant-Abutment connection level: An in vitro study of the efficacy of three different implant systems. *Journal of Biological Regulators and Homeostatic Agents*. 2016;30:69-73.
94. El Haddad E, Gianni AB, Mancini GE, et al. Implant-abutment leaking of replace conical connection nobel biocare® implant system. An in vitro study of the microbiological penetration from external environment to implant-abutment space. *ORAL and Implantology*. 2016;9:76-82.
95. Mancini GE, Gianni AB, Cura F, et al. Efficacy of a new implant-abutment connection to minimize microbial contamination: An in vitro study. *ORAL and Implantology*. 2016;9:99-105.
96. Roncati M, Lucchese A, Carinci F. Non-Surgical treatment of peri-Implantitis with the adjunctive use of an 810-nm diode laser. *Journal of Indian Society of Periodontology*. 2013;17:812-815.
97. Scarano A, Tripodi D, Carinci F, et al. Biofilm formation on titanium alloy and anatase-Bactercline® coated titanium healing screws: An in vivo human study. *Journal of Osseointegration*. 2013;5:8-12.
98. Brunelli G, Carinci F, Zollino I, et al. Sem evaluation of 10 infected implants retrieved from man. *European Journal of Inflammation*. 2012;10:7-12.
99. Scarano A, Sinjari B, Di Orio D, et al. Surface analysis of failed oral titanium implants after irradiated with ErCr:ysgg 2780 laser. *European Journal of Inflammation*. 2012;10:49-54.
100. Brunelli G, Carinci F, Zollino I, et al. Peri-implantitis. A case report and literature review. *European Journal of Inflammation*. 2012;10:1-5.
101. Scarano A, Piattelli A, Polimeni A, et al. Bacterial adhesion on commercially pure titanium and anatase-coated titanium healing screws: An in vivo human study. *Journal of Periodontology*. 2010;81:1466-1471.
102. Grecchi F, Zollino I, Candotto V, et al. A case of mandible osteonecrosis after a severe periimplant infection. *Dent Res J (Isfahan)*. 2012;9:S233-236.
103. Carinci F, Farina A, Zanetti U, et al. Alveolar ridge augmentation: a comparative longitudinal study between calvaria and iliac crest bone grafts. *J Oral Implantol*. 2005;31:39-45.
104. Carinci F, Pezzetti F, Volinia S, et al. Analysis of MG63 osteoblastic-cell response to a new nanoporous implant surface by means of a microarray technology. *Clinical Oral Implants Research*. 2004;15:180-186.
105. Oliveira DP, Palmieri A, Carinci F, et al. Osteoblasts behavior on chemically treated commercially pure titanium surfaces. *J Biomed Mater Res A*. 2014;102:1816-1822.
106. Andreasi Bassi M, Lopez MA, Confalone L, et al. Hydraulic sinus lift technique in future site development: clinical and histomorphometric analysis of human biopsies. *Implant Dent*. 2015;24:117-124.
107. El Haddad E, Lauritano D, Carinci F. Interradicular septum as guide for pilot drill in postextractive implantology: a technical note. *J Contemp Dent Pract*. 2015;16:81-84.
108. Azzi L, Carinci F, Gabaglio S, et al. Helicobacter pylori in periodontal pockets and saliva: A possible role in gastric infection relapses. *Journal of Biological Regulators and Homeostatic Agents*. 2017;31:257-262.
109. Tettamanti L, Gaudio RM, Iapichino A, et al. Genetic susceptibility and periodontal disease: A retrospective study on a large italian sample. *ORAL and Implantology*. 2017;10:20-27.

110. Tettamanti L, Gaudio RM, Cura F, et al. Prevalence of periodontal pathogens among Italian patients with chronic periodontitis: A retrospective study on 2992 patients. *ORAL and Implantology*. 2017;10:28-36.
111. Gargari M, Comuzzi L, Bazzato MF, et al. Treatment of peri-implantitis: Description of a technique of surgical 2 detoxification of the implant. A prospective clinical case series with 3-year follow-up. *ORAL and Implantology*. 2015;8:1-11.
112. Grecchi F, Perale G, Candotto V, et al. Reconstruction of the zygomatic bone with Smartbone®: case report. *Journal of biological regulators and homeostatic agents*. 2015;29(3 Suppl 1):42-7.
113. Lauritano D, Avantaggiato A, Candotto V, et al. Insulin activity on dental pulp stem cell differentiation: an in vitro study. *Journal of biological regulators and homeostatic agents*. 2015;29 (3 Suppl 1):48-53.
114. Baj A, Trapella G, Lauritano D, Candotto V, et al. An overview on bone reconstruction of atrophic maxilla: success parameters and critical issues. *Journal of biological regulators and homeostatic agents*. 2016;30(2 Suppl 1):209-215.
115. Baj A, Lo Muzio L, Lauritano D, et al. Success of immediate versus standard loaded implants: a short literature review. *Journal of biological regulators and homeostatic agents*. 2016;30(2 Suppl 1):183-188.
116. Lauritano D, Avantaggiato A, Candotto V, et al. Effect of somatostatin on dental pulp stem cells. *Journal of biological regulators and homeostatic agents*. 2015;29(3 Suppl 1):54-58.
117. Tettamanti L, Bassi MA, Trapella G, et al. Applications of biomaterials for bone augmentation of jaws: clinical outcomes and in vitro studies. *Oral Implantol (Rome)*. 2017 Apr 10;10(1):37-44. eCollection 2017 Jan-Mar.

Correspondence to:

Francesco Carinci
Department of Morphology, Surgery and Experimental
Medicine
University of Ferrara
Via Luigi Borsari 46
44100 Ferrara, Italy
Phone: +39.0532.455874; Fax: +39.0532.455876
E-mail: crc@unife.it