

# UNEXPECTED ARTEFACTS AND OCCULT PATHOLOGIES UNDER CBCT

L. LOMBARDO<sup>1</sup>, A. ARREGHINI<sup>1</sup>, M.P. GUARNERI<sup>1</sup>, D. LAURITANO<sup>2</sup>, M. NARDONE<sup>3</sup>, G. SICILIANI<sup>1</sup>

<sup>1</sup> Department of Orthodontics, University of Ferrara, Ferrara, Italy

<sup>2</sup> Department of Translational Medicine and Surgery, Neuroscience Center of Milan, University of Milano Bicocca, Monza, Italy

<sup>3</sup> Ministry of Public Health, Rome, Italy

## SUMMARY

**Purpose.** To present the most frequent occult pathologies unexpectedly encountered via cone-beam computed tomography (CBCT), with particular reference to the diagnostic role of the dentist and that of the radiographer, with a view to clarifying where the diagnostic responsibility lies.

**Material and methods.** A narrative literature review on the most diffused occult pathologies under CBCT was conducted, with iconographical guide as an example for each category.

**Results.** The most frequent forms of unexpected pathologies encountered are: the presence of foreign bodies, airway anomaly, and the presence of radio-opacity or -transparency in the maxillofacial district.

**Conclusions.** The orthodontists must know that they are responsible to recognize these frequent, and potentially serious, pathologies of the head and neck. If the dentist feels unable to take on this responsibility, he or she should, however, be sure to have the scans read by a specialist radiologist.

**Key words:** cone-beam computed tomography, occult pathologies, orthodontic.

## Introduction

The superiority of cone-beam computed tomography (CBCT) with respect to traditional two-dimensional radiographic techniques is well known throughout the scientific community (1-3). In addition to being more precise and reliable, the information provided by this technique is also greater in *quantity*. In fact, whereas orthopantomograms and telerradiograms can be viewed by an experienced clinician in relatively little time, CBCT can involve the analysis of over 500 axial, sagittal and coronal sections (4).

Furthermore, CBCT scans the entire head and neck district, including anatomical structures of little orthodontic interest. However, this means that dentists are in a very good position to encounter occult pathologies, which, despite being outside their direct sphere of expertise, cannot remain undiagnosed.

Thus, the increasingly diffuse use of CBCT, very often in young patients, forces the clinician to undertake serious ethical and medicolegal reflection (5-10). Among the most evident issues to be addressed is whether the training a dentist has undergone makes him or her able to recognize these frequent, and potentially serious, pathologies of the head and neck, or whether referral to a radiographic specialist would be more opportune. In fact, to date, the respective responsibilities of the person who commissions and the person who performs a volumetric scan still remain to be clarified. In addition, CBCT should be carefully evaluated in syndromic patients (11-34).

Hence, the aim of this study was to present the most frequent occult pathologies unexpectedly encountered via CBCT, with particular reference to the diagnostic role of the dentist and that of the radiographer, with a view to clarifying where the diagnostic responsibility lies.

## Occult pathologies evidence by CBCT

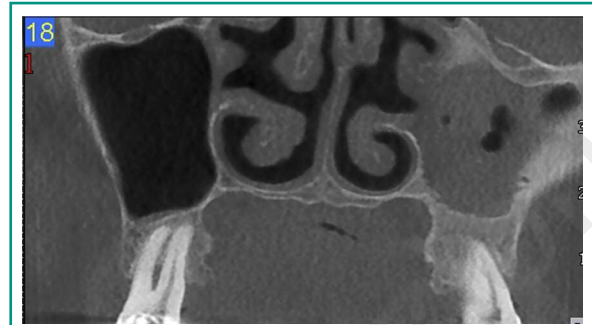
The occasional discovery of occult pathologies upon commissioning orthodontic X-rays is a widespread and well-known occurrence. Indeed, a study conducted by Bondemark in 2006 showed that the OPTs of 8.7% of 496 orthodontic patients displayed anomalies other than those for which the X-ray was commissioned (35). According to Tetradis (1999), on the other hand, careful evaluation of laterolateral telerradiograms can reveal cranial calcifications, sinus problems or hypertrophic adenoids or tonsils in 8-18% of patients (36). More recently, however, the diffusion of CBCT has broadened the investigative field, and therefore multiplied the range of pathologies that can be diagnosed. The potential for encountering unexpected pathologies has therefore tripled, from 8 to 24% of patients (37).

The pathologies encountered unexpectedly by CBCT are usually asymptomatic, and can be divided into two categories: those considered to be variations in normal anatomy with no consequences for the patient, and those requiring specialist referral before dental treatment can be commenced. An example of the latter could be sinusitis in patients scheduled for miniscrew implantation in the upper jaw; in this case the sinusitis needs to be resolved in order to improve the chances of successful implantation or orthodontic treatment.

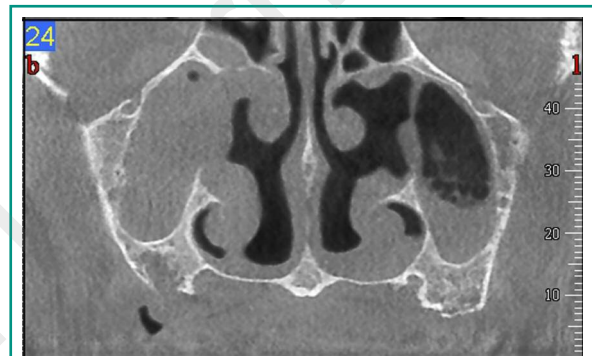
In the worst case scenario, serious pathologies that put the life of the patient at risk, such as plaques in the carotid arteries or tumours, can be encountered, necessitating the postponement or suspension of the planned treatment and immediate referral to a specialist (38).

The most frequent forms of unexpected pathologies encountered are: the presence of foreign bodies, dental abnormalities, airway anomaly, TMD, cervical vertebrae anomaly, and the presence of radio-opacity or -transparency in the maxillofacial district (39).

Performing CBCT (Figures 1, 2) permits the identification of foreign bodies in maxillary sinus and



**Figure 1**  
Foreign body visible under CBCT.



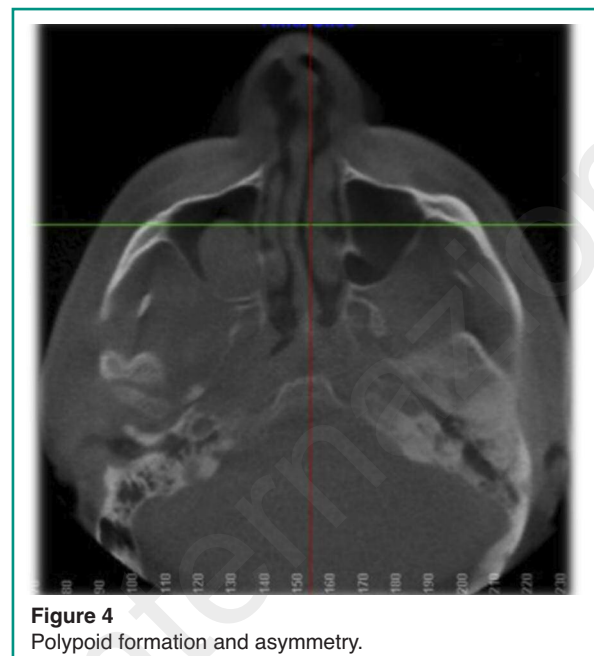
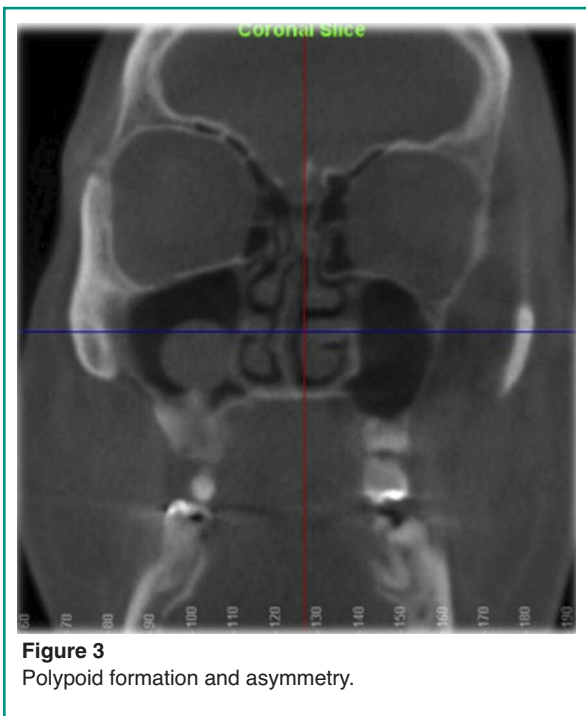**Figure 2**  
Foreign body visible under CBCT.

also to be defined in relation to the surrounding structures.

Airway disorders (sinusitis, nasal polyps, deviated septa, hypertrophic adenoids or tonsils, mucosal retention cysts) are also frequently observed, especially in adolescent patients between 12 and 16 years of age. For instance, Figures 3-5 show a case of severe asymmetry between the left and right maxillary sinuses.

In addition (Figures 3-5) CBCT can evidence invagination of the maxillary sinus between the roots of the first molars, a strong contraindication for treatments such as molar distalization (40).

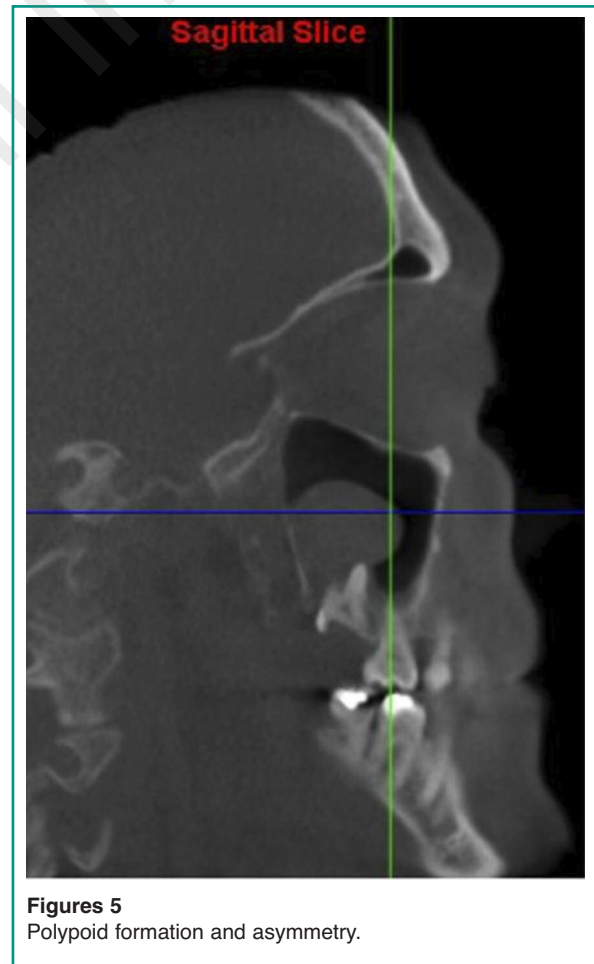
Cervical vertebrae anomalies uncovered by volumetric scans, on the other hand, are more common, and could be indicators of various disorders, for example Klippel-Feil syndrome, a congenital disease causing the fusion of at least two cervical vertebrae. Abnormalities of the odontoid process of the



epistropheus could also be the result of a congenital condition, or of a traumatic event. Despite the potential severity of these conditions, which may compromise the stability of the spine, their incidence is difficult to evaluate in that these alterations are almost always asymptomatic (41).

Asymptomatic areas of radio-transparency, usually without risk to the patient's health, include Stafne cysts and ossification defects of the parietal bone. These do, however, require referral for more in-depth diagnostic analysis (42, 43).

A far more frequent, and potentially very serious, occult pathology is the presence of calcifications in the carotid arteries. Carotid stenosis and consequent arterial plaque fragmentation are the cause of almost one half of all cardiac infarctions. As calcification at the carotid sinus can be seen under OPT, it should be unfailingly evident to the expert eye under CBCT. Due to its aetiology, this is a condition that affects adult patients (2% of all dentistry patients and 5% of over-55-year olds). However, it must be borne in mind whenever a scan for implantation purposes is performed as early diagnosis, and consequent referral to a specialist, greatly influences the survival prospects of the patient (38).



## Discussion

CBCT is becoming increasingly common as a diagnostic aid in dental and orthodontic patients and oral surgery especially in cases requiring dental implant positioning (44-85).

The most advanced models of this type of scanner permit definition of the field-of-view (FOV), which is generally between 6 and 12 inches, but it tends to be greater in dental investigations, as the jaws, paranasal (and frontal) sinuses, upper airways and condyles may all be of interest. This means that the dentist is in an excellent position, and therefore has the ethical obligation, to evaluate all sections taken in search of occult pathologies, which are by no means rare (86).

What the dentist should do with this information, however, does require further clarification. Naturally, orthodontists will not be expected to provide an accurate diagnosis of conditions falling outside their sphere of expertise. Nevertheless, familiarity with the normal anatomy of the head and neck is their obligation, and they should be duty bound to recognize any abnormality and consequently refer the patient to the appropriate specialist (87).

In such matters, the guidelines set out by the European Academy of DentoMaxilloFacial Radiology are explicit: points 17 and 18 stress the importance of suitable and continuous training for all dentists involved in the use of CBCT, not only as regards the use of the machines themselves, but also, and especially, concerning the interpretation of the resulting images (18). Moreover, points 19 and 20 of these guidelines clarify the current trend in the division of responsibilities: restricted FOVs, involving only the jaws, are within the field of expertise of both the expert dentist and the radiologist specialized in the maxillofacial district. It is suggested, on the other hand, that scans with larger FOVs be analysed by a radiology specialist (88).

From a legal perspective, dentists as well as radiologists may own a CBCT scanner (87). If a dentist does not, however, possess one, patients can be sent either to a better-equipped colleague

or to a radiological institute, armed with a specific request.

However, in order to circumvent potential legal issues, some radiological centres issue radiographic images for dental use specifying that they have not been examined by a radiologist, making them merely an aid to implantation, extraction or other orthodontic treatment. In these cases, if a patient desires a specialist reading, they are forced to expressly request the services of a radiologist and pay the corresponding fee. However, this 'solution' is indefensible from a medicolegal standpoint as the clinician who has commissioned the scan is considered responsible for analysing all the data provided (89). Furthermore, the specialist who performs the scan has the same degree of responsibility as the dentist who commissioned it as regards verification of the reasons behind the examination and in ensuring complete reading of the slices, thereby effectively providing the patient with a double guarantee (90).

Thus, the international trend is to safeguard the patient as much as possible, ensuring that the scans are examined by the most competent professional, expert in the body district in question, and sharing the responsibility between all the clinicians involved in requesting and performing the diagnostic investigation.

## Conclusions

Although widespread dissemination of CBCT scanning within the field of dentistry, particularly in orthodontics, has considerably increased the diagnostic potential, several ethical and medical-legal issues have consequently come to the fore.

In fact, professionals exploiting such a technique can often encounter occult pathologies, which cannot be left undiagnosed.

According to legal guidelines, the responsibility for diagnosing such pathologies is shared by all the specialists involved in the investigation.

In particular, when using large field-of-views,



dentists must be able to recognize such occult pathologies, even if they fall outside their direct sphere of expertise. Even if the dentist feels unable to take on this responsibility, he or she should, however, be responsible for having the scans read by a specialist radiologist.

Indeed, although no universal international law yet governs these matters, the current trend is to safeguard the patient, entrusting the correct reading of three-dimensional scans to appropriately trained specialists.

## References

1. Kapila S, Conley RS, Harrell WE, Jr. The current status of cone beam computed tomography imaging in orthodontics. *Dentomaxillofac Radiol.* 2011;40:24-34.
2. Pauwels R, Beinsberger J, Collaert B, et al. Effective dose range for dental cone beam computed tomography scanners. *Eur J Radiol.* 2012;81:267-71.
3. Koong B. Cone beam imaging: is this the ultimate imaging modality? *Clin Oral Implants Res.* 2010;21:1201-08.
4. Miles DA. Interpreting the Cone Beam Data Volume for occult pathology. *Semin Orthod.* 2009;15:70-76.
5. Gaudio RM, Barbieri S, Feltracco P, et al. Impact of alcohol consumption on winter sports-related injuries. *Med Sci Law.* 2010;50:122-5.
6. Gaudio RM, Barbieri S, Feltracco P, et al. Traumatic dental injuries during anaesthesia. Part II: medico-legal evaluation and liability. *Dent Traumatol.* 2011;27:40-5.
7. Feltracco P, Gaudio RM, Barbieri S, et al. The perils of dental vacation: possible anaesthetic and medicolegal consequences. *Med Sci Law.* 2013;53:19-23.
8. Andreasi Bassi M, Andrisani C, Lopez MA, Gaudio RM, Lombardo L, Lauritano D. Guided bone regeneration in distal mandibular atrophy by means of a preformed titanium foil: a case series. *J Biol Regul Homeost Agents.* 2016;30:61-8.
9. Andreasi Bassi M, Andrisani C, Lopez MA, Gaudio RM, Lombardo L, Lauritano D. Endoscopically controlled hydraulic sinus lift in combination with rotary instruments: one-year follow-up of a case series. *J Biol Regul Homeost Agents.* 2016;30(S2):21-8.
10. Andreasi Bassi M, Andrisani C, Lopez MA, Gaudio RM, Lombardo L, Carinci F. Guided bone regeneration by means of a preformed titanium foil: A case of severe atrophy of edentulous posterior mandible. *J Biol Regul Homeost Agents.* 2016;30 (S2):35-41.
11. Grecchi F, Zollino I, Perrotti V, Carinci F. Williams-Beuren syndrome treated with orthognathic surgery and combined partial glossectomy: Case report. *Journal of Osseointegration.* 2011;3:91-94.
12. Grecchi F, Mancini GE, Bianco R, Zollino I, Carinci F. Distraction osteogenesis therapy in patients affected by Goldenhar syndrome: A case series. *Journal of Osseointegration.* 2011;3:30-34.
13. Carinci P, Becchetti E, Baroni T, et al. Extracellular matrix and growth factors in the pathogenesis of some craniofacial malformations. *European Journal of Histochemistry.* 2007;51:105-16.
14. Lilli C, Bellucci C, Baroni T, et al. FGF2 effects in periosteal fibroblasts bearing the FGFR2 receptor Pro253 Arg mutation. *Cytokine.* 2007;38:22-31.
15. Carinci F, Pezzetti F, Locci P, et al. Apert and Crouzon syndromes: Clinical findings, genes and extracellular matrix. *Journal of Craniofacial Surgery.* 2005;16:361-68.
16. Baroni T, Carinci P, Lilli C, et al. P253R fibroblast growth factor receptor-2 mutation induces RUNX2 transcript variants and calvarial osteoblast differentiation. *Journal of Cellular Physiology.* 2005;202:524-35.
17. Scapoli L, Martinelli M, Pezzetti F, et al. Spontaneous expression of FRA3P in a patient with Nager syndrome [1]. *American Journal of Medical Genetics.* 2003;118 A:293-95.
18. Baroni T, Lilli C, Marinucci L, et al. Crouzon's syndrome: Differential in vitro secretion of bFGF, tgfb $\beta$  isoforms and extracellular matrix macromolecules in patients with FGFR2 gene mutation. *Cytokine.* 2002; 19:94-101.
19. Carinci F, Bodo M, Tosi L, et al. Expression profiles of craniosynostosis-derived fibroblasts. *Molecular Medicine.* 2002;8:638-44.
20. Bodo M, Bellocchio S, Carinci F, et al. Basic fibroblast growth factor: Effects on matrix remodeling, receptor expression, and transduction pathway in human periosteal fibroblasts with FGFR2 gene mutation. *Journal of Interferon and Cytokine Research.* 2002;22:621-30.
21. Bodo M, Baroni T, Carinci F, et al. Interleukin secretion, proteoglycan and procollagen  $\alpha$ (I) gene expression in Crouzon fibroblasts treated with basic fibroblast growth factor. *Cytokine.* 2000;12:1280-83.
22. Carinci F, Hassanipour A, Mandrioli S, Pastore A. Surgical treatment of choanal atresia in CHARGE association: Case report with long-term follow-up. *Journal of Cranio-Maxillofacial Surgery.* 1999;27:321-26.
23. Bodo M, Baroni T, Carinci F, et al. A regulatory role of fibroblast growth factor in the expression of decorin, biglycan, betaglycan and syndecan in osteoblasts from patients with Crouzon's syndrome. *European Journal of Cell Biology.* 1999;78:323-30.
24. Mandrioli S, Carinci F, Dalleria V, Calura G. Fibrous dysplasia. The clinico-therapeutic picture and new data on its etiology. A review of the literature. *Minerva*

- stomatologica. 1998;47:37-44.
25. Bodo M, Carinci F, Baroni T, et al. Interleukin pattern of Apert fibroblasts in vitro. *European Journal of Cell Biology*. 1998;75:383-88.
  26. Bodo M, Carinci F, Baroni T, et al. Apert's syndrome: Differential in vitro production of matrix macromolecules and its regulation by interleukins. *European Journal of Clinical Investigation*. 1997;27:36-42.
  27. Bodo M, Carinci F, Baroni T, et al. Effects of interleukins on crouzon fibroblast phenotype in vitro. Release of cytokines and IL-6 mRNA expression. *Cytokine*. 1996;8:772-83.
  28. Carinci F, Felisatti P, Curioni C. A case of lingual agenesis. *Minerva stomatologica*. 1996;45:359-62.
  29. Carinci F, Curioni C. A case of hemifacial oculo-oral anomalies. *Minerva stomatologica*. 1996;45:281-83.
  30. Avantaggiato A, Carinci F, Curioni C. Apert's syndrome: Cephalometric evaluation and considerations on pathogenesis. *Journal of Craniofacial Surgery*. 1996;7:23-31.
  31. Carinci F, Avantaggiato A, Curioni C. Crouzon syndrome: Cephalometric analysis and evaluation of pathogenesis. *Cleft Palate-Craniofacial Journal*. 1994;31:201-09.
  32. Martinelli M, Scapoli L, Palmieri A, et al. Study of four genes belonging to the folate pathway: transcobalamin 2 is involved in the onset of non-syndromic cleft lip with or without cleft palate. *Human mutation*. 2006;27:294.
  33. Caruso S, Storti E, Nota A, Ehsani S, Gatto R. Temporomandibular joint anatomy assessed by CBCT images. *BioMed Research International*. 2017, 2017.
  34. Giuca MR, Inglese R, Caruso S, Gatto R, Marzo G, Pasini M. Craniofacial morphology in pediatric patients with Prader-Willi syndrome: a retrospective study. *Orthodontics and Craniofacial Research*. 2016;19:216-21.
  35. Bondemark L, Jepbondpsson M, Lindh-Ingildsen L, Rangne C. Incidental findings of pathology and abnormality in pretreatment orthodontic panoramic radiographs. *Angle Orthod*. 2006;76:98-102.
  36. Tetradis S, Kantor ML. Prevalence of skeletal and dental anomalies and normal variants seen in cephalometric and other radiographs of orthodontic patients. *Am J Orthod Dentofacial Orthop*. 1999;116:572-7.
  37. Cha JY, Mah J, Sinclair P. Incidental findings in the maxillofacial area with 3-dimensional cone-beam imaging. *Am J Orthod Dentofacial Orthop*. 2007;132:7-14.
  38. Almog DM, Illig KA, Khin M, Green RM. Unrecognized carotid artery stenosis discovered by calcifications on a panoramic radiograph. *J Am Dent Assoc*. 2000;131:1593-7.
  39. Rogers SA, Drage N, Durning P. Incidental findings arising with cone beam computed tomography imaging of the orthodontic patient. *Angle Orthod*. 2011;81:350-5.
  40. Bosio JA, Tanaka O, Rovigatti E, de Gruner SK. The incidence of maxillary sinus retention cysts in orthodontic patients. *World J Orthod*. 2009;10:e7-8.
  41. Tetradis S, Kantor ML. Anomalies of the odontoid process discovered as incidental findings on cephalometric radiographs. *Am J Orthod Dentofacial Orthop*. 2003;124:184-9.
  42. Luker J, McNamara T, Sandy J. Holes in the head: parietal foramina, a developmental anomaly seen during a routine orthodontic assessment. *Int J Paediatr Dent*. 1998;8:209-11.
  43. Smith MH, Brooks SL, Eldevik OP, Helman JI. Anterior mandibular lingual salivary gland defect: a report of a case diagnosed with cone-beam computed tomography and magnetic resonance imaging. *Oral Surg Oral Med Oral Pathol Oral Radiol Endod*. 2007;103:e71-8.
  44. Haney E, Gansky SA, Lee JS, Johnson E, Maki K, Miller AJ, Huang JC. Comparative analysis of traditional radiographs and cone-beam computed tomography volumetric images in the diagnosis and treatment planning of maxillary impacted canines. *Am J Orthod Dentofacial Orthop*. 2010;137:590-7.
  45. Lucchese A, Carinci F, Saggese V, Lauritano D. Immediate loading versus traditional approach in functional implantology. *European Journal of Inflammation*. 2012;10:55-58.
  46. Traini T, Danza M, Zollino I, et al. Histomorphometric evaluation of an immediately loaded implant retrieved from human mandible after 2 years. *International Journal of Immunopathology and Pharmacology*. 2011;24:31-36.
  47. Scarano A, Murrura G, Carinci F, Lauritano D. Immediately loaded small-diameter dental implants: evaluation of retention, stability and comfort for the edentulous patient. *European Journal of Inflammation*. 2012;10:19-23.
  48. Degidi M, Piattelli A, Carinci F. Clinical outcome of narrow diameter implants: a retrospective study of 510 implants. *J Periodontol*. 2008;79:49-54.
  49. Degidi M, Piattelli A, Iezzi G, Carinci F. Do longer implants improve clinical outcome in immediate loading? *Int J Oral Maxillofac Surg*. 2007;36:1172-6.
  50. Degidi M, Piattelli A, Carinci F. Immediate loaded dental implants: comparison between fixtures inserted in postextractive and healed bone sites. *J Craniofac Surg*. 2007;18:965-71.
  51. Degidi M, Piattelli A, Iezzi G, Carinci F. Retrospective study of 200 immediately loaded implants retaining 50 mandibular overdentures. *Quintessence Int*. 2007;38:281-8.
  52. Degidi M, Piattelli A, Iezzi G, Carinci F. Immediately loaded short implants: analysis of a case series of 133 implants. *Quintessence Int*. 2007;38:193-201.
  53. Degidi M, Piattelli A, Iezzi G, Carinci F. Wide-diameter implants: Analysis of clinical outcome of 304 fixtures. *Journal of Periodontology*. 2007;78:52-58.
  54. Degidi M, Piattelli A, Gehrke P, Felice P, Carinci F.

- Five-year outcome of 111 immediate nonfunctional single restorations. *J Oral Implantol.* 2006;32:277-85.
55. Degidi M, Piattelli A, Carinci F. Parallel screw cylinder implants: Comparative analysis between immediate loading and two-stage healing of 1005 dental implants with a 2-year follow up. *Clinical Implant Dentistry and Related Research.* 2006;8:151-60.
  56. Degidi M, Piattelli A, Gehrke P, Carinci F. Clinical outcome of 802 immediately loaded 2-stage submerged implants with a new grit-blasted and acid-etched surface: 12-month follow-up. *Int J Oral Maxillofac Implants.* 2006;21:763-8.
  57. Degidi M, Piattelli A, Felice P, Carinci F. Immediate functional loading of edentulous maxilla: a 5-year retrospective study of 388 titanium implants. *J Periodontol.* 2005;76:1016-24.
  58. Rigo L, Viscioni A, Franco M, Lucchese A, Zollino I, Brunelli G, Carinci F. Overdentures on implants placed in bone augmented with fresh frozen bone. *Minerva Stomatol.* 2011;60:5-14.
  59. Carinci F, Brunelli G, Franco M, Viscioni A, Rigo L, Guidi R, Strohmer L. A retrospective study on 287 implants installed in resorbed maxillae grafted with fresh frozen allogeneous bone. *Clin Implant Dent Relat Res.* 2010;12:91-8.
  60. Viscioni A, Rigo L, Franco M, Brunelli G, Avantaggiato A, Sollazzo V, Carinci F. Reconstruction of severely atrophic jaws using homografts and simultaneous implant placement: a retrospective study. *J Oral Implantol.* 2010;36:131-9.
  61. Franco M, Rigo L, Viscione A, et al. CaPO4 blasted implants inserted into iliac crest homologue frozen grafts. *The Journal of oral implantology.* 2009;35:176-80.
  62. Viscioni A, Franco M, Rigo L, Guidi R, Brunelli G, Carinci F. Implants inserted into homografts bearing fixed restorations. *Int J Prosthodont.* 2009;22:148-54.
  63. Franco M, Viscioni A, Rigo L, Guidi R, Zollino I, Avantaggiato A, Carinci F. Clinical outcome of narrow diameter implants inserted into allografts. *J Appl Oral Sci.* 2009;17:301-6.
  64. Viscioni A, Franco M, Rigo L, Guidi R, Spinelli G, Carinci F. Retrospective study of standard-diameter implants inserted into allografts. *J Oral Maxillofac Surg.* 2009;67:387-93.
  65. Carinci F, Brunelli G, Zollino H, et al. Mandibles grafted with fresh-frozen bone: An evaluation of implant outcome. *Implant Dentistry.* 2009;18:86-95.
  66. Carinci F, Brunelli G, Zollino I, et al. Mandibles grafted with fresh-frozen bone: an evaluation of implant outcome. *Implant Dent.* 2009;18:86-95.
  67. Franco M, Tropina E, De Santis B, Viscioni A, Rigo L, Guidi R, Carinci F. A 2-year follow-up study on standard length implants inserted into alveolar bone sites augmented with homografts. *Stomatologija.* 2008;10:127-32.
  68. Danza M, Paracchini L, Carinci F. Tridimensional finite element analysis to detect stress distribution in implants. *Dental Cadmos.* 2012;80:598-602.
  69. Danza M, Grecchi F, Zollino I, Casadio C, Carinci F. Spiral implants bearing full-arch rehabilitation: Analysis of clinical outcome. *Journal of Oral Implantology.* 2011;37:447-55.
  70. Danza M, Zollino I, Avantaggiato A, Lucchese A, Carinci F. Distance between implants has a potential impact of crestal bone resorption. *Saudi Dental Journal.* 2011;23:129-33.
  71. Carinci F, Danza M. Clinical outcome of implants inserted in piezo split alveolar ridges: A pilot study. *Perspectives on Clinical Dentistry.* 2011:29-30.
  72. Danza M, Zollino I, Guidi R, Carinci F. Computer planned implantology: Analysis of a case series. In: ed. eds. *Perspectives on Clinical Dentistry.* 2011:287-300.
  73. Danza M, Carinci F. Flapless surgery and immediately loaded implants: a retrospective comparison between implantation with and without computer-assisted planned surgical stent. *Stomatologija.* 2010;12:35-41.
  74. Danza M, Quaranta A, Carinci F, Paracchini L, Pompa G, Voza I. Biomechanical evaluation of dental implants in D1 and D4 bone by Finite Element Analysis. *Minerva stomatologica.* 2010;59:305-13.
  75. Danza M, Riccardo G, Carinci F. Bone platform switching: a retrospective study on the slope of reverse conical neck. *Quintessence Int.* 2010;41:35-40.
  76. Danza M, Fromovich O, Guidi R, Carinci F. The clinical outcomes of 234 spiral family implants. *J Contemp Dent Pract.* 2009;10:E049-56.
  77. Calvo-Guirado JL, Ortiz-Ruiz AJ, Lopez-Mari L, Delgado-Ruiz R, Mate-Sanchez J, Bravo Gonzalez LA. Immediate maxillary restoration of single-tooth implants using platform switching for crestal bone preservation: a 12-month study. *Int J Oral Maxillofac Implants.* 2009;24:275-81.
  78. Danza M, Guidi R, Carinci F. Comparison Between Implants Inserted Into Piezo Split and Unsplit Alveolar Crests. *Journal of Oral and Maxillofacial Surgery.* 2009;67:2460-65.
  79. Danza M, Scarano A, Zollino I, Carinci F. Evaluation of biological width around implants inserted in native alveolar crest bone. *Journal of Osseointegration.* 2009;1:73-76.
  80. Danza M, Zollino I, Guidi R, Carinci F. A new device for impression transfer for non-parallel endosseous implants. *Saudi Dental Journal.* 2009;21:79-81.
  81. Andreasi Bassi M, Lopez MA, Confalone L, Gaudio RM, Lombardo L, Lauritano D. Clinical outcome of a two-piece implant system with an internal hexagonal connection: a prospective study. *J Biol Regul Homeost Agents.* 2016;30:7-12.
  82. Danza M, Guidi R, Carinci F. Spiral family implants inserted in postextraction bone sites. *Implant Dent.* 2009;18:270-8.
  83. Andreasi Bassi M, Andrisani C, Lico S, Ormanier Z, Barlattani A, Ottria L. Endoscopic management of the Schneiderian membrane perforation during transcres-

- sinus augmentation: A case report. *ORAL and Implantology*. 2016;9:157-63.
84. Clementini M, Ottria L, Pandolfi C, Bollero P. A Novel Technique to Close Large Perforation of Sinus Membrane. *ORAL and Implantology*. 2013;6:11-14.
  85. Clementini M, Ottria L, Pandolfi C, Agrestini C, Bartattani A. Four impacted fourth molars in a young patient: a case report. *Oral Implantol (Rome)*. 2012;5:100-3.
  86. Macdonald-Jankowski DS, Orpe EC. Some current legal issues that may affect oral and maxillofacial radiology. Part 2: digital monitors and cone-beam computed tomography. *J Can Dent Assoc*. 2007;73:507-11.
  87. Friedland B. Medicolegal issues related to cone beam CT. *Semin Orthod*. 2009;15:77-84.
  88. Horner K, Islam M, Flygare L, Tsiklakis K, Whites E. Basic principles for use of dental cone beam computed tomography: consensus guidelines of the European Academy of Dental and Maxillofacial Radiology. *Dentomaxillofac Radiol*. 2009;38:187-95.
  89. Friedland B. Conebeam computed tomography: legal considerations. *Alpha Omegan*. 2010;103:57-61.
  90. Holroyd JR, Gulson AD. The radiation protection implications of the use of Cone Beam Computed Tomography (CBCT) in Dentistry – What you need to know. 2007.

---

*Correspondence to:*  
Luca Lombardo, DDS  
Department of Orthodontics  
University of Ferrara  
Via Montebello 31  
44100 Ferrara, Italy  
Phone: +39 (0532) 202.528; Fax: +39 (0532) 202.528  
E-mail: lulombardo@tiscali.it