GASTRO

Openventio PUBLISHERS

http://dx.doi.org/GOJ/GOJ-1-101

Open Journal

Case Report

*Corresponding Author:
Fabio Pagni, MD
Department of Surgery and Interdisciplinary Medicine Pathology
University Milan Bicocca
San Gerardo Hospital
20900, Monza, Italy
E-mail: Fabio.pagni@unimib.it

Volume 1 : Issue 1
Article Ref. #: 1000GOJ1101

Article History:
Received: 24th April, 2014
Accepted: 20th May, 2014
Published: 29h May, 2014

Citation:
Jaconi M, Frego R, Pagni F. Duodenal Amyloidotic Tumor. *Gastro Open J*. 2014; 1(1): 1-2.

Duodenal Amyloidotic Tumor

Marta Jaconi[1], Roberto Frego[2] and Fabio Pagni[1*]

[1]Department of Pathology, University Milan Bicocca, San Gerardo Hospital, Monza, Italy

[2]Endoscopy Unit, San Gerardo Hospital, Monza, Italy

DESCRIPTION OF THE CASE

This duodenal polypoid lesion was found during Esophago Gastro Duodenoscopy (EGDS) performed in a 77-year-old woman (Figure 1, A). Our patient had already been diagnosed with multiple myeloma a few years earlier; although treated with multiple lines of treatment, the disease was still in progression with multiple vertebral localizations and renal failure. She started complaining of asthenia and suffered from various episodes of melena over two weeks; the Emergency Room assessment found Deep Venous Thrombosis (DVT) and severe anemization (Hb 5.9 g/dl). After stabilization with 3 blood transfusions, she underwent an EGDS to localize the source of bleeding. The polypoid lesion that was found underwent biopsy because it raised suspicions of localization of myeloma, primary tumor of the duodenum or infectious disease. Histology, instead, excluded the presence of a neoplastic tumor, but revealed massive mucosal and submucosal deposits of an amorphous eosinophilic substance (Figure 1, B), that showed apple-green birefringence on staining with Congo red (Figure 1, C and D). A diagnosis of tumoral intestinal AL amyloidosis was made.

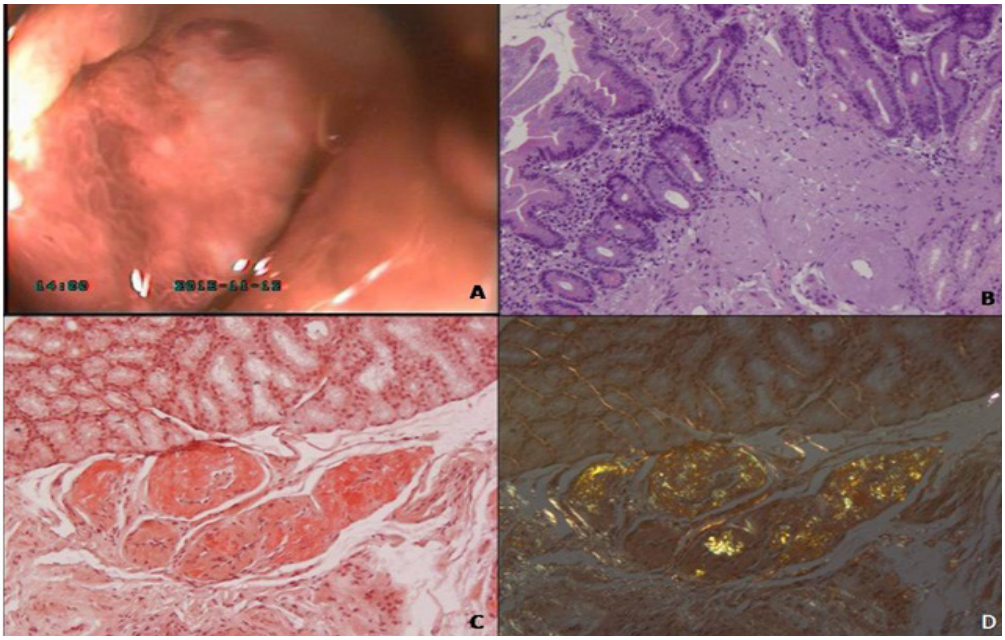

Figure 1: A: Endoscopic appearance of this duodenal polypoid vegetant lesion; B: Haematoxylin & Eosin stain revealed absence of malignancy; the pseudotumoral appearance was due to the presence of abundant amorphous material consistent with amyloid; C-D: Congo Red histochemistry confirmed the morphological suspicion.

DISCUSSION

Primary amyloidosis is the most common form of amyloidosis and the only form that occurs with multiple myeloma. It is caused by fragments of abnormal antibodies (light

chains). Amyloid can form deposits in loidosis and the only form that occurs with multiple myeloma. It is caused by fragments of abnormal antibodies (light chains). Amyloid can form deposits in different organs such as kidneys, liver, myocardial tissue, skin and peripheral nervous system; our patient lacked involvement of these typical organs. Gastrointestinal (GI) involvement is quite rare, occurring in approximately 8% of patients,[1] and often subclinical. The mass-forming pattern is even rarer, as in the majority of cases the deposits are linear, presenting themselves as mucosal thickening and enlarged folds.[2] The most common symptoms of GI amyloidosis are weight loss, diarrhea, malabsorption, pseudo-obstruction, perforation and gastrointestinal bleeding, associated with vascular friability.[3,4] At endoscopy, GI amyloidosis can mimic many benign and malignant diseases, including ulcerative, flat or vegetant tumours. Only the histological examination allows the formulation of a correct diagnosis and a proper treatment, particularly in these solitary presentations.[5] We report this case as an example of an uncommon but peculiar diagnostic pitfall, which in literature has been referred to as "amyloidoma". Amyloidotic tumors, being able to trick both clinical examination and imaging, share this feature with other non- neoplastic lesions such as GI xanthomas, inflammatory and lymphoid polyps, heterotopic gastric or pancreatic tissues.[6] All these occurrences have also in common the need for biopsies in order to establish their true nature. However, patients with GI amyloidosis and evidence of active GI bleeding or ulceration are not offered myeloablative chemotherapy, because of the risk of catastrophic GI hemorrhage.[7] Patients who are not candidates for chemoterapic regimens, are usually treated in clinical trials with novel agents or with melphalan and dexamethasone.[7]

REFERENCES

1. Menke DM, Kyle RA, Fleming CR, Wolfe JT. Symptomatic gastric amyloidosis in patients with primary systemic amyloidosis. *Mayo Clin Proc*. 1993; 68(8): 763-767.

2. Rivera R, Kaul V, DeCross A, Whitney-Miller C. Primary gastric amyloidosis presenting as an isolated gastric mass. *Gastrointestinal Endoscopy*. 2012; 76: 186-187.

3. Gould M, Zarrin-Khameh N, Sellin J. Small bowel amyloidosis. *Curr Gastroenterol Rep*. 2013; 15(10): 350.

4. Sawada T, Adachi Y, Akino K, et al. Endoscopic features of primary amyloidosis of the stomach. *Endoscopy*. 2012; 44: s2: 275-276.

5. Ali MF, Patel A, Muller S, Friedel D. Rare presentation of primary (AL) amyloidosis as gastrointestinal hemorrhage without systemic involvement. *World J Gastrointest Endosc*. 2014; 6(4): 144-147.

6. Sattianayagam P, Hawkins P, Gillmore J. Amyloid and the GI tract. *Expert Rev Gastroenterol Hepatol*. 2009; 3(6): 615-630.

7. Cowan AJ, Skinner M, Seldin DC, et al. Amyloidosis of the gastrointestinal tract: a 13-year, single-center, referral experience. *Haematologica*. 2013; 98(1): 141-146.