

Case Report

Dental fragment embedded in the lower lip after facial trauma: Brief review literature and report of a case

Dorina Lauritano¹, Massimo Petruzzi², Gerardo Sacco³, Guglielmo Campus⁴, Francesco Carinci⁵, Lucio Milillo⁶

¹Departments of Dentistry, University of Milano Bicocca, Milan, ²Methodologies and Medical Surgical Technologies, University of Bari, ³Private Practice, Dentis, Bari, ⁴Dentistry, University of Sassari, Sassari, ⁵Department of Medical-Surgical Sciences of Communication and Behavior, Section of Maxillofacial and Plastic Surgery, University of Ferrara, Ferrara, ⁶Surgical Sciences, University of Foggia, Foggia, Italy

ABSTRACT

Upper incisors are the most frequently involved teeth in traumatic dental injuries. Soft tissues (lips and/or oral mucosa) adjacent to incisal edge can receive direct and/or indirect traumas. Laceration of the lower lip is a not rare eventuality and teeth fragments could be embedded in labial soft tissue. The reattachment of these fragments, if possible, is the elective treatment choice, thanks to the modern adhesive and restorative techniques. The authors present a case of a white Caucasian 10-year-old child, who attended the dental clinic for the treatment of both upper central incisors' crown fractures. The fragment of the left incisor was retrieved embedded in the lower lip. It was successfully surgically removed and reattached using a composite adhesive technique. A careful clinical and radiographic examination with the surgical removal of tooth fragments could prevent undesirable foreign body reaction, infection and scarring. The authors also reviewed the most relevant literature concerning tooth fragment reattachment after removal from oral soft tissues.

Key Words: Crown fracture, dental trauma, tooth fragment, tooth reattachment

Received: September 2012
Accepted: November 2012

Address for correspondence:
Prof. Francesco Carinci,
Department of Morphology,
Surgery and Experimental
Medicine, University of
Ferrara, Corso della Giovecca
203, 44100 Ferrara, Italy.
E-mail: crc@unife.it

INTRODUCTION

Approximately 50% of children under 15 years are victims of various kinds of injuries and traumas in the orofacial region.^[1] Traumatic dental injuries represent main cause of emergency treatments in dental practice.^[2,3] Incisors are frequently involved, and uncomplicated or complicated crown fractures usually are due to traffic accidents and sports injuries. Unlike the lower lip, upper lip does not entirely cover the coronal portion of the incisors and this results in less protection from injuries.^[4,5]

Prevalence of the incisors' traumas among childhood and adolescence ranges from 7 to 33%, according to gender and age of individuals.^[6]

Trauma may involve labial tissues directly or indirectly: Marginal edges are the main cause of this indirect trauma to the lower lip. About 50% of traumatic injuries to permanent incisors are associated to labial laceration and bleeding or soft tissue trauma.^[7] Crown fragments may displace in oral soft tissues remaining included; for this reason, simple soft tissue radiograph could be useful in the fragments detection. After a trauma also the eruption of a definitive tooth should be studied.^[8-14]

The authors present a case of two uncomplicated crown fractures whereas one of the tooth fragments was retrieved from the lower lip of a child involved in a sport accident. Furthermore, authors have reviewed the literature studies and reports related to teeth fragments reattachment after removal of oral soft tissues.

CASE REPORT

A white Caucasian 10-year-old boy was admitted to the Dental Clinic at the University of Bari (Policlinico), Italy, complaining of a firm mass in the lower lip, painless and recovered by a squamous-crusty lesion.

Access this article online



Website: www.drj.ir

Both the central incisors appeared fractured. His mother reported that the boy had fallen while playing football the day before the visit and she collected a single tooth fragment stored in a paper tissue. There was no history of other previous injuries and no symptoms of concussion. Lip examination revealed a laceration on the left side of the lower lip. A firm nodule, measuring approximately 1 cm in diameter in the same region was noted. Intra-oral examination revealed an Ellis class II fracture of the permanent right and left maxillary central incisors [Figure 1]. All maxillary incisors teeth responded promptly to the pulp tests. A lateral soft tissue radiograph and a periapical radiograph of the maxillary central incisors were performed. There were no signs of root fractures or other periapical diseases but the presence of a tooth fragment in the lower lip was confirmed [Figure 2]. An antibiotic (clavulanic acid plus amoxicillin 500 mg t.i.d.) and anti-inflammatory therapy (ketoprofen 40 mg) was prescribed and the patient was discharged and readmitted the next day.

Under regional block anesthesia, the wound site was cleansed with a chlorhexidine solution 0.2%, and a small horizontal incision was made. The tooth fragment was retrieved and gently removed. The wound was irrigated with saline and a 4-0 black silk suture was placed.

The tooth fragment embedded in the lip corresponded to the upper central left incisor [Figure 3], while the fragment recovered by the patient's mother belonged to the upper central right incisor. Both teeth fragments were stored in saline solution and re-attached in the same session, separately, using for each one, the procedure described by Rappelli *et al.*^[15] According to these authors, the operating field was isolated with a rubber dam and the fractured portion of the teeth fragments was etched with a 37% orthophosphoric acid gel for 30 s followed by gentle rinsing. A bonding system was then applied to the etched surfaces without polymerization. The fractured margins of the two central incisors were treated with a 'total etch technique': 30 s of etching for enamel and 15 s for dentine. An adhesive system was applied to the etched surfaces. Each fragment was then accurately placed on the original position and a single photo-polymerization was completed in 40 s. A bevel was performed along the fracture line to improve aesthetics according to Andreasen *et al.*^[16]

After the adhesive resin was placed, a compound resin of transparent dye was applied to cover

the demarcation line between the glued surfaces. Polishing and finishing were performed by using fine grain disks and decreasing grain adamantine pastes applied with dedicated rotating felts. The final result was satisfying on esthetic and functional profile [Figure 4].

The patient was reviewed on a regular basis for over a year: No symptoms, no tenderness to percussion, absence of mobility and a positive reaction to pulp testing were found.

DISCUSSION

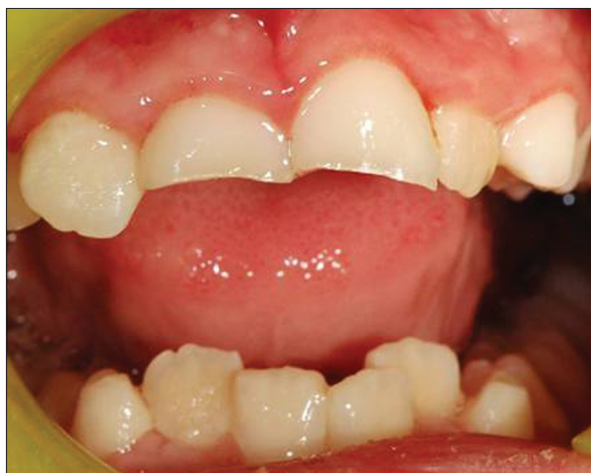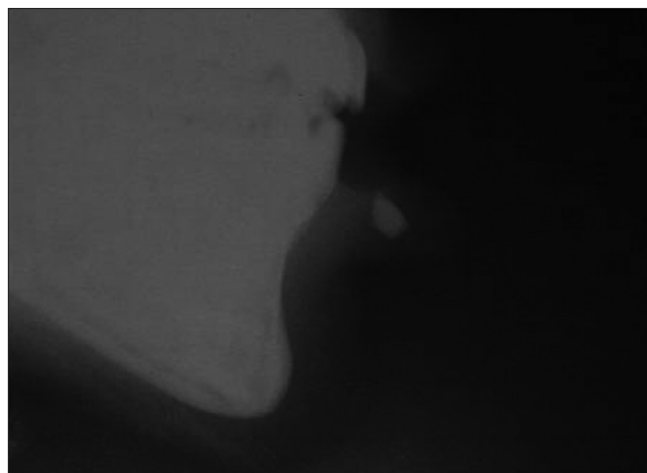
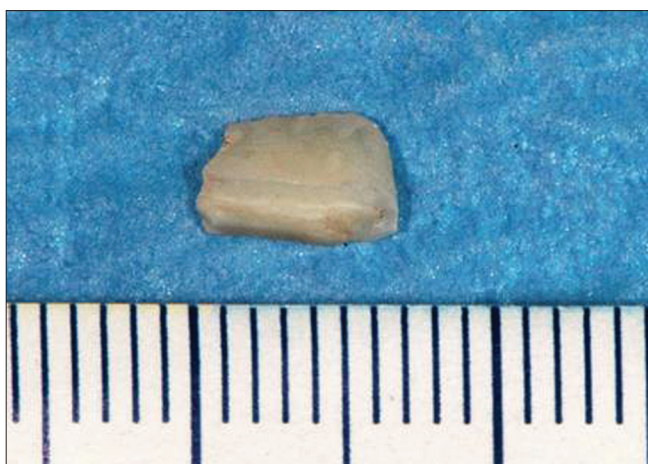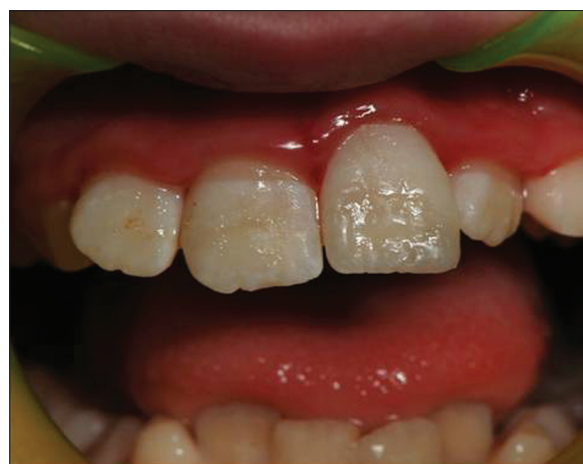In clinical practice, uncomplicated crown fractures can be treated either by reshaping the sharp edges or, in cases of greater loss of dental tissue, by an acid-etched composite restoration.^[4] Incisal edge reattachment, if the tooth fragment is available, remains the first choice treatment, above all in children.^[17,18] As a matter of fact, it is a conservative technique that does not preclude, in case of failure, the use of other treatment options or even the repetition of the reattachment itself.^[19,20] The esthetic properties of the fractured tooth are preserved because the fragment has the same color as the rest of the tooth and the incisal edge translucency is maintained. Moreover, Sengun *et al.* demonstrated that reattachment of fractured incisal fragments by using new generation bonding agents is effective against shear stresses, at levels which are comparable with those of the intact teeth. They concluded that instead of a composite restoration, the reattachment of a fractured fragment is preferable.^[21]

The authors have performed a literature review, which confirms the propriety of this clinical approach. Available studies about teeth fragment retrieved in oral soft tissue and reattached are summarized in Table 1 and there are at least four published reports of tooth fragments embedded in the lip and reattached.

The first report was described more than thirty years ago by Mader.^[22] He described a fragment of a fractured central incisor found in the lower lip three years after the original trauma. The fragment was surgically removed from the lip and reattached to the crown using the acid-etch resin technique. The author prophesized: "It is hoped that in the future new materials and techniques will be perfected so that... (dentist) will be able to restore them (portions of teeth) in their original position. Pasini *et al.*,^[23] reported an immediate reattachment of an incisal edge

Table 1: Published literature concerning tooth fragment reattachment after surgical removal

Authorss	Patient sex and age (yrs)	Involved mucosa	Involved tooth	Type of fracture	Follow up	Type of treatment
Mader (11)	Male 27	Lower lip	21	Uncomplicated	3 month	reattached
Pasini (12)	Female 18	Lower lip	12	Uncomplicated	1 year	reattached
Naudi (13)	Male 11	Lower lip	11	Uncomplicated	1 year	reattached
Schwengber (14)	Male 8	Lower lip	21	Complicated	1 year	reattached
Present case	Male 10	Lower lip	21	Uncomplicated	1 year	reattached

**Figure 1:** Clinical appearance of the fractured maxillary central incisors at presentation**Figure 2:** Preoperative lateral x-ray of the soft tissues showed the localization of the tooth fragment in lower lip**Figure 3:** Recovered fragment of the upper central left fractured incisor**Figure 4:** Clinical appearance of upper right and left central incisors after teeth fragments reattachment

of a lateral incisor retrieved in the lower lip. They defined their procedure as “first choice treatment” for coronal fractures emphasizing the importance of dental fragment storage and the multidisciplinary nature of dental trauma management. Naudi and Fung^[24] reported the first pediatric case in which they described the reattachment of a tooth fragment embedded in the lower lip, 3 hours after the initial trauma. The authors reported that there were no dental and esthetic complications for over one year.

Recently, Schwengber *et al.*^[25] describes a case of a pediatric patients who presented a nodule on his lower lip as consequence of retained incisal fragment embedded until 2 months. The tooth was devitalized and before performing the tooth fragment reattachment, the gutta percha was removed with a heated curette below the gingival line to avoid crown darkening. Finally, the fragment was reattached by using an adhesive technique and one-year follow-up results were satisfactory.

Usually a fractured or missed incisor does not pose any problem in diagnosis. However, in case of concomitant soft tissue laceration, the possible presence of tooth fragments in the lacerated soft tissues should be suspected.^[26] Tooth fragments embedded in soft tissue may not be easily detectable clinically. Laceration, bleeding and patient discomfort make post-traumatic evaluation difficult, and a simple soft tissue and occlusal radiograph could be useful in detection of embedded teeth fragments in the oral regions. The most frequent site of fragment inclusion is the lower lip; however, the tongue may also be involved.^[27]

Their recognition and identification is important because the continuous movement of contraction of the *orbicularis oris* muscle may dislocate these “foreign bodies”. Moreover, the oral bacterial flora can infect the wound and the deep tissues. Failure to remove totally the portions of teeth embedded in the soft tissue may result in a breakdown of the suture line, persistent chronic infection and discharge and a disfiguring fibrosis.

CONCLUSION

Several cases of spontaneous eruption of undetected tooth fragments from soft tissue as a consequence of a misdiagnosis are reported in the literature.^[28] This scenario could be avoided through a detailed history of the accident, a careful physical observation and a simple radiographic examination of soft tissues.

REFERENCES

- Andreasen JO, Andreasen FM, Andersson L. Traumatic injuries to the teeth. Copenhagen: Munksgaard; 2007.
- Bauss O, Rohling J, Schwestka-Polly R. Prevalence of traumatic injuries to the permanent incisors in candidates for orthodontic treatment. Dent Traumatol 2004;20:61-6.
- Caprioglio C, Caprioglio D. The dental trauma. Dentistry for the pediatrician. Pacini Ed. Pisa; 2008. p. 97-114.
- Caprioglio C, Caprioglio A, Caprioglio D. Esthetics in pediatric dentistry. In: Goldstein RE, editor. Esthetics in dentistry. Ontario: BC Decker Inc; 2011.
- De Fabianis P. Oro-dento-facial traumatology in growing patients. Milano: Quintessenza Ed. srl; 2009.
- Tapias MA, Jimenez-Garcia R, Lamas F, Gil AA. Prevalence of traumatic crown fractures to permanent incisors in a childhood population: Mostoles, Spain. Dent Traumatol 2003;19:119-22.
- Zerman N, Cavalleri G. Traumatic injuries to permanent incisors. Endod Dent Traumatol 1993;9:61-4.
- Lucchese A, Manuelli M. Prediction of eruption or impaction of the third molar: Comparative analysis. Prog Orthod 2003;4:4-19.
- Lucchese A, Carinci F, Brunelli G, Monguzzi R. An *in vitro* study of resistance to corrosion in brazed and laser welded orthodontic. Europ J Inflamm 2011;9:67-72.
- Lucchese A, Carinci F, Brunelli G, Monguzzi R. EverstickÒ and RibbondÒ fiber reinforced composites: Scanning electron microscope (sem) comparative analysis. Eur J Inflamm 2011;9:73-80.
- Palmieri A, Zollino I, Clauser L, Lucchese A, Girardi A, Farinella F, *et al.* Biological effects of resorbable plates on normal osteoblasts and osteoblasts derived from Pfeiffer syndrome. J Craniofac Surg 2011;22:1-4.
- Lucchese A, Sfondrini MF, Manuelli M, Gangale S. Fixed space maintainer for use with a rapid palatal expander. J Clin Orthod 2005;39:557-8.
- Sollazzo V, Pezzetti F, Massari L, Palmieri A, Brunelli G, Zollino I, *et al.* Evaluation of gene expression in MG63 human osteoblastlike cells exposed to tantalum powder by microarray technology. Int J Periodontics Restorative Dent 2011;31:e17-28.
- Lucchese A, Storti E. Morphological characteristics of primary enamel surfaces versus permanent enamel surfaces: SEM digital analysis. Eur J Paediatr Dent 2011;12:179-83.
- Rappelli G, Massaccesi C, Putignano A. Clinical procedures for the immediate reattachment of a tooth fragment. Dent Traumatol 2002;18:281-4.
- Andreasen FM, Noren JG, Andreasen JO, Engelhardtson S, Lindh-Stromberg U. Long-term survival of fragment bonding in the treatment of fractured crowns: A multicenter clinical study. Quintessence Int 1995;26:669-81.
- Flores MT, Andreasen JO, Bakland LK, Feiglin B, Gutmann JL, Oikarinen K, *et al.* Guidelines for the evaluation and management of traumatic dental injuries. Dent Traumatol 2001;17:49-52.
- Tsukiboshi M. Treatment planning of traumatized teeth. Tokio: Quintessence Publishing Co. Inc; 1998.
- Farik B, Munksgaard EC, Andreasen JO. Fracture strength of fragment-bonded teeth. Effect of calcium hydroxide lining before bonding. Am J Dent 2000;13:98-100.
- Reis A, Francci C, Loguercio AD, Carrilho MR, Rodrigues Filho LE. Re-attachment of anterior fractured teeth: Fracture strength using different techniques. Oper Dent 2001;26:287-94.
- Sengun A, Ozer F, Unlu N, Ozturk B. Shear bond strengths of tooth fragments reattached or restored. J Oral Rehabil 2003;30:82-6.
- Mader C. Restoration of a fractured anterior tooth. J Am Dent Assoc 1978;96:113-5.
- Pasini S, Bardellini E, Keller E, Conti G, Flocchini P, Majorana A. Surgical removal and immediate reattachment of coronal fragment embedded in lip. Dent Traumatol 2006;22:165-8.
- Naudi AB, Fung DE. Tooth fragment reattachment after retrieval from the lower lip-a case report. Dent Traumatol 2007;23:177-80.
- Schwengber GF, Cardoso M, Vieira Rde S. Bonding of fractured permanent central incisor crown following radiographic localization of the tooth fragment in the lower lip: A case report. Dent Traumatol 2010;26:434-7.
- da Silva AC, de Moraes M, Bastos EG, Moreira RW, Passeri LA. Tooth fragment embedded in the lower lip after dental trauma: Case reports. Dent Traumatol 2005;21:115-20.

27. Hill FJ, Picton JF. Fractured incisor fragment in the tongue: A case report. *Pediatr Dent* 1981;3:337-8.
28. Rao D, Hegde S. Spontaneous eruption of an occult incisor fragment from the lip after eight months: Report of a case. *J Clin Pediatr Dent* 2006;30:195-7.

How to cite this article: Lauritano D, Petruzzi M, Sacco G, Campus G, Carinci F, Milillo L. Dental fragment embedded in the lower lip after facial trauma: Brief review literature and report of a case. *Dent Res J* 2012;9:S237-41.

Source of Support: Nil. **Conflict of Interest:** None declared.

Announcement

Android App



Download
**Android
application**

FREE

A free application to browse and search the journal's content is now available for Android based mobiles and devices. The application provides "Table of Contents" of the latest issues, which are stored on the device for future offline browsing. Internet connection is required to access the back issues and search facility. The application is compatible with all the versions of Android. The application can be downloaded from <https://market.android.com/details?id=comm.app.medknow>. For suggestions and comments do write back to us.