


VOLUMETTO ESTRATTO DA:

# XXVIII WORLD CONGRESS OF THE INTERNATIONAL COLLEGE OF SURGEONS

Cairo-Egypt  
November 16-21, 1992



MONDUZZI EDITORE

# Surgical therapy and prognostic considerations in the treatment of pheochromocytomas and paragangliomas

S. MIANI, G.F. GIUFFRIDA, M. ERBA,  
P. MINGAZZINI, M. BONESCHI and U. RUBERTI

*Istituto di Chirurgia Generale e Cardiovascolare, Milano (I)*

## SUMMARY

The Authors present their experience with eighty patients, affected by neoplasms involving the adrenal medulla and the multicentric paragangliar system, observed and surgically treated during the last twenty-five years.

Fifty patients were affected by hyperincretory forms.

Thirty patients presented silent cervical paragangliomas.

This study is aimed at analyzing the evolution of the diagnostic techniques, the clinical picture, the adopted surgical procedure and the results obtained.

Finally because it is well known that the classic histological study is not sufficient to define the benign or malignant nature of the neoplastic transformations the Authors began an immunohistochemical research in order to demonstrate the relative percentage of "sustentacular" cells inside the paragangliar tissue.

A decrease of this type of cells seems to be correlated with a more malignant attitude of the tumor.

The knowledge of the histological structure of the paraganglia could therefore be useful in determining the prognosis of these tumors.

## INTRODUCTION

Pheochromocytomas result from the neoplastic transformation of adrenal medulla with consequent catecholamine hyperincretion and development of a complex of symptoms defined as "pheochromocytoma syndrome". These neoplasms typically arise in the adrenal medulla but other tumors arising elsewhere in the body and referred to as extra-adrenal "paragangliomas" can either hyperincrete catecholamines (20% of paragangliomas) or be functionally "silent" (80% of them).

Pheochromocytomas and paragangliomas embryologically derive from cells

of the primitive neuroectoderm (neural crest), that differentiate to form either adrenal medullary chromaffin cells or extra adrenal paraganglionic cells.

The capacity of synthesizing peptidic hormones by means of a process of decarboxylation of amine precursors taken up from circulatory stream led Pearse to formulate the APUD system theory in order to unify and include cells so apparently different.

Among the tumors of extra-adrenal paraganglia, generally those arising in the posterior mediastium and in the retroperitoneum are hyperincretory; on the contrary those located in the cervical region are rarely functioning.

This study is aimed at analyzing our series of adrenal and extra-adrenal pheochromocytomas, examining their location, the clinical picture, the adopted surgical procedure and the results obtained.

Particular attention has been recently paid to the immunohistochemical studies, in order to derive information that could be useful in determining the prognosis.

## MATERIALS AND METHODS

During the last twenty-five years at the Istituto di Chirurgia Generale e Cardiovascolare, University of Milan, 43 patients affected by adrenal pheochromocytomas and seven by functioning extra-adrenal paragangliomas have been observed and surgically treated (fig. 1).

Three patients of this group presented a bilateral adrenal neoplasm; in another three patients an involvement of contralateral gland was found sometime after adrenalectomy (recurrent pheochromocytomas).

In one patient the pheochromocytoma was associated with Von Recklinghausen's neurofibromatosis.

Forty-eight patients presented a clinical picture according to classic pheochromocytoma syndrome.

Only two patients were asymptomatic: a case of adrenal incidentaloma appeared later to be a pheochromocytoma after histological examination; in the second case a double abdominal paraganglioma was incidentally found during the diagnostic investigations performed in order to detect the nature of a macroscopic hematuria.

Twenty-two patients were male; 28 female. The youngest patient was thirteen years old; the oldest seventy-one. The mean age was 39 years.

Thirty-two patients presented a stable hypertensive condition (arterial pressure levels ranging between 160/100 and 250/150 mmHg); fourteen of these also presented hypertensive paroxysmal attacks.

Sixteen patients basally normotensive referred hypertensive crises.

Moreover, fifteen patients complained of headaches, twenty tachycardia and twelve sweating crises.

In thirty-nine cases the ECG demonstrated signs of cardiac overload. Nine patients complained of retinopathy.

All of these patients underwent a surgical intervention.

In three cases a second intervention was necessary owing to the contralateral recurrence of the pheochromocytoma.

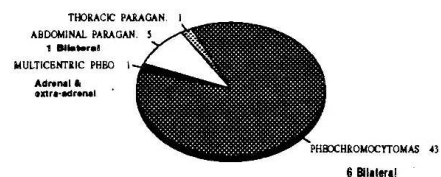
The mortality rate was four percent; two patients died:

- a woman, 32 years old, operated on in emergency following the angiographic examination that triggered a hypertensive paroxysmal attack unresolved by medical therapy; the patient underwent myocardial fibrillation and died.

- a man that in the immediate post-operative course underwent a fatal cerebral hemorrhage in the territory of the middle cerebral artery.

In all the patients affected by sustained hypertension or by paroxysmal

SURGICAL TREATMENT OF PHEOCHROMOCYTOMAS & PARANGLIOMAS  
HYPERSECRETING TUMORS  
50 PATIENTS (58 Tumors)



contrast medium may stimulate the release of catecholamines and induce an hypertensive crisis.

Recently the somatostatin receptor imaging has been detected in the most of the paragangliar neoplasms, in the carcinoids and in the endocrine pancreas neoplasias.

All the pheochromocytomas, on the contrary, are without such receptors.

In silent cervical paragangliomas the diagnosis was always made after angiography. In fact the typical enlargement of the carotid bifurcation, associated with the presence of a fine vascular network in the examined mass, is practically conclusive from the diagnostic point of view.

Quite recently the angio RNM allows precise visualization of the analyzed district and also provides informations about contralateral carotid axis and the intracerebral vascularization.

We believe that the surgical treatment is mandatory in all functioning neoplasms due to the severity of organic damages induced by the high pressure levels, the scant efficacy of the medical therapy and the possibility of a malignant transformation of these tumors (10% of the cases according to the literature).

Also in the non functioning forms the surgical removal represents the therapeutic solution of choice not only for the potential malignancy of these lesions but also for the possibility of damages due to the dislodgement of nervous, vascular or visceral structures determined by the progressive enlargement of the neoplastic mass.


Although most paragangliomas are benign, in many circumstances the malignancy of the tumor is related to its location, like for carotid body or jugular glomus neoplasms.

Nevertheless the knowledge of the malignancy of the tumor has a great importance for the prognosis, in order to be able to predict the clinical outcome for the patient.

Unfortunately a peculiar tract of these paragangliomas, like for other neuroendocrine tumors, is that features which are characteristic of malignant neoplasms, such as nuclear atypias and variations in the nuclear to cytoplasmic ratio, may be seen also in benign paragangliomas.

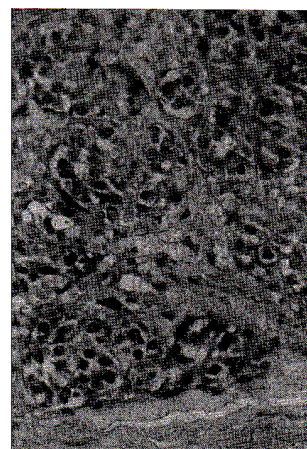
The usual histological criteria are therefore useless to recognize tumors that are likely to metastasize.

Fig. 3



Identification by immunohistological means of the chief cells.

Fig. 4



The presence of some sustentacular cells predicts a benign clinical behaviour of this cervical paraganglioma.

Both normal tissue and neoplastic, show an organoid pattern of chief cells, containing neurosecretory granules, arranged in cell nests, surrounded by sustentacular cells.

Chief cells contain neuron specific enolase, chromogranin and leu-enkefalin, while sustentacular cells contain S-100 protein (1-2-3-4).

Previous studies made the observation that staining intensity of chief cells for chromogranin and the relative number of sustentacular cells, diminish in neoplastic as compared to normal tissue, furthermore metastasizing pheochromocytomas are either devoid or markedly depleted of sustentacular cells (5).

Immunohistochemistry, using a panel of antisera to neuron-specific enolase (NSE), chromogranin and meta-enkefalin, or toward S-100 protein and glial fibrillary acid protein (GFAP) can clearly identify chief and sustentacular cells.

Kliwer and Associates (6) were thus able, using immunohistochemical techniques in paragangliomas, to give an indication of the likely prognosis for the patients.

In more recent cases of our series we performed, on surgical specimens, routine histology, transmission electron microscopy, and immunochemistry using antibodies to neuron specific enolase (NSE) to identify chief cells (Fig 3) and antibodies to S-100 protein to point out sustentacular cells (Fig.4).

Our patients are periodically reviewed in a careful follow up in order to convalidate the prognosis obtained by means of immunohistologic criteria.

## REFERENCES

- 1) VINOES S.A.,BOHUIN J.M.,RUBINSTEIN L.J.:Immunohistochemical demonstration of neuron-specific enolase in neoplasms of the CNS and other tissues. Arch.Pathol.Lab.Med. 108:536-540,1984
- 2) HAMID Q.A.,BISHOP A.E.,RADE J.:Duodenal gangliocytic paragangliomas. A study of 10 cases with immunocytochemical neuroendocrine markers. Hum. Pathol. 17:1151-1157,1986.
- 3) DE LELLIS R.A., TISCLER A.S., LEE A.K.: Leu-enkefalin-like immunoreactivity in proliferative lesions of the human adrenal medulla and extra-adrenal paraganglia. Am. J. Surg. Pathol. 7:29-37,1983
- 4) KAHN J.H.,MARKAS A., THOM H.: Role of antibody to S-100 protein in diagnostic pathology. Am.J.Clin.Pathol.79:341-347,1983
- 5) LLOYD R.V.,BLAIVAS M., WILSON B.S.:Distribution of chromogranin and S-100 protein in normal and abnormal adrenal medullary tissues. Arch.Pathol.Lab.Med.:109:633-635,1985.
- 6) KLEWER K.E.,COCHRAN A.J.:A review of the histology, ultrastructure, immunohistology and molecular biology of extra-adrenal paragangliomas.Arch. Pathol. Lab. Med. 113: 1209-1217,1989.