Neurophysiologie Clinique/Clinical Neurophysiology (2019) 49, 217—226

Disponible en ligne sur
ScienceDirect
www.sciencedirect.com

Elsevier Masson France
EM|consulte
www.em-consulte.com/en

ORIGINAL ARTICLE

# Brainstem evoked potentials and magnetic resonance imaging abnormalities in differential diagnosis of intracranial hypotension

**Vincenzo Di Stefano**[a,b,*], **Camilla Ferrante**[a,b], **Roberta Telese**[a,b], **Massimo Caulo**[a,c], **Laura Bonanni**[a,b], **Marco Onofrj**[a,b], **Raffaella Franciotti**[a,c]

[a] *Department of Neuroscience, Imaging and Clinical Sciences, ''G. d'Annunzio'' University, Chieti, Italy*
[b] *Aging Research Centre, Ce.S.I., ''G. d'Annunzio'' University, Chieti, Italy*
[c] *Institute for Advanced Biomedical Technologies (ITAB), ''G. d'Annunzio'' University, Chieti, Italy*

Reçu le 12 janvier 2019 ; accepté le 25 avril 2019
Disponible sur Internet le 14 May 2019

**KEYWORDS**
Brainstem acoustic evoked potential ;
Chiari malformation ;
Intracranial hypotension ;
Magnetic resonance imaging ;
Sensorineural hearing loss

**Summary**
*Objective.* — To compare brainstem acoustic evoked potentials (BAEP) and magnetic resonance imaging (MRI) in the differential diagnosis of intracranial hypotension (IH), Chiari malformation (CM) and sensorineural hearing loss (SNHL).
*Methods.* — BAEP were recorded in 18 IH, 18 CM, 20 SNHL patients and 52 controls. MRI were acquired in all IH and CM patients.
*Results.* — Abnormal BAEP were observed in 94% of IH patients, in 33% of CM and 70% of SNHL patients. After recovery from IH, BAEP abnormalities disappeared. Internal auditory canal (IAC) MRI abnormalities were described in 88% of IH patients. MRI signs of IH were observed in 33—78% in IH patients, but the most frequent MRI sign was 8th nerve T2 hyperintensity, with contrast enhancement in T1 sequences. This finding, combined with wave I latency, yielded highest specificity and sensitivity for IH diagnosis.

* Corresponding author at: Department of Neuroscience, Imaging and Clinical Science, ''G. d'Annunzio'' University, Via Luigi Polacchi, 66013 Chieti, Italy.
*Adresse e-mail :* Vincenzo19689@gmail.com (V. Di Stefano).

https://doi.org/10.1016/j.neucli.2019.04.003
0987-7053/© 2019 The Authors. Published by Elsevier Masson SAS. This is an open access article under the CC BY-NC-ND license (http://creativecommons.org/licenses/by-nc-nd/4.0/).

*Conclusions*. — Our study points out how IH can be effectively distinguished from CM and SNHL through the contribution of neurophysiology and MRI; in particular, evaluation of the 8th nerve achieves a high sensitivity and specificity in patients with IH. Further studies are required to examine the combined use of BAEP recordings ad MRI in diagnosis and monitoring of patients affected by IH.
© 2019 Les Auteurs. Publié par Elsevier Masson SAS. Cet article est publié en Open Access sous licence CC BY-NC-ND (http://creativecommons.org/licenses/by-nc-nd/4.0/).

## Introduction

Intracranial hypotension (IH) is a condition caused by low cerebrospinal fluid (CSF) pressure or CSF leakage, which usually resolves after CSF pressure normalization [15]. Symptoms are variable and non-specific and include positional headache (usually orthostatic), neck stiffness and pain, hearing changes, tinnitus, photophobia, nausea and, in rare cases, coma [14,18,39,40,42]. Magnetic resonance imaging (MRI) is the gold standard for the diagnosis of IH and allows demonstration of subdural effusions, enhancement of meninges, engorgement of venous structures, sagging of the brain and the venous distension sign [12,14,18,39,42]. However, typical MRI abnormalities are found only in 68—85% of patients with IH [12,14,18,39,42]. For this reason, recent studies focused on alternative diagnostic techniques in order to improve diagnosis [32].

A pilot study by our research group examined the clinical utility of brainstem acoustic evoked potentials (BAEP) in association with internal auditory canal (IAC) MRI in patients with IH [25]. BAEP are far-field potentials generated in internal ear and brainstem, and could track eighth cranial nerve and brainstem distortions observed in IH [20,28]. We hypothesized that hearing changes, which are a typical symptom of IH, could indicate internal auditory canal (IAC) alterations in IH; for this reason, patients with IH were evaluated through evoked potentials and MRI resulting in specific abnormalities [13,15]. Of interest, it was reported that alterations in the first component of BAEP were associated with 8th cranial nerve hyperintensity on MRI during IH status. Furthermore, abnormalities on BAEP, consisting of delayed wave I and either normal or (less frequently) delayed latencies of the subsequent components disappeared following recovery from IH [25]. However, no further data exist in the literature concerning BAEP alterations in IH and several conditions could mimic the described pattern of BAEP and MRI alterations. In fact, patients with IH share MRI findings with patients with Chiari malformation (CM), where tonsillar descent/brainstem sagging is a typical finding [23], making differential diagnosis between the two conditions necessary. Similarly, distinction would also be needed from sensorineural hearing loss (SNHL), which typically presents with low amplitude or absent early (wave I and II) BAEP components [6,27].

The goal of the present study was to assess the specificity of BAEP abnormalities in IH, comparing with BAEP findings observed in CM and in patients with SNHL, and to compare our results to MRI findings.

## Methods

The study was performed according to the declaration of Helsinki and its later amendments, and it was approved by the local ethical committee. Informed consent was obtained from each subject included in the study.

### Patient selection

All consecutive patients aged 18—80 years who received a diagnosis of IH were enrolled. Age-matched healthy controls were selected from our normative population [24,36]. We selected from our diagnostic archives CM patients without IH and patients with bilateral SNHL to intermediate- and high-frequency stimuli (28—65 dB loss) due to cochlear pathology [24,36]. CM patients were diagnosed according to clinical and MRI criteria, showing cerebellar tonsillar descent through the foramen occipitalis [23].

### Evoked potentials

BAEP were recorded according to standard guidelines [1] and previous studies on normative populations [3—5,7,8,10,11,16,19,20,22,26,28,30,31,33,35,41]. For each subject the auditory function was assessed by determining the auditory threshold. Then, the auditory nerve was stimulated by square wave clicks of alternating stimulus polarity through conventional audiometric earphones. The stimulus was applied at 90 dB sensation level (SL, which indicates the subject's individual threshold) above the click-hearing threshold at a repetition rate of 10 Hz. The contralateral ear was masked by white noise at 60 dB. Surface electrodes were placed at the vertex (Cz) and on each earlobe (A1 and A2) to record the auditory waveforms. Channel derivations include ipsilateral ear to vertex and contralateral ear to vertex. An external ear canal supplementary electrode was used to preserve wave I morphology. The recordings were bandpass filtered at 200—2000 Hz and 2000—4000 trials were averaged in a period of 10 ms from the onset of the stimulus. In IH patients BAEP recordings were performed during occurrence of symptoms and 15—30 days after full recovery. In all controls, BAEP recordings were repeated after 30—210 days to obtain an index of test/retest variability and to allow comparison with changes in IH patients after recovery.

## Magnetic resonance imaging

In all IH and CM patients, MRI was performed using a 3T scanner with an 8-channel head coil. Axial turbo spin echo (TSE) T2-weighted and spectral adiabatic inversion recovery (SPAIR) sequences were acquired together with a pre- and post-contrast 3D fast Field echo (FFE) T1-weighted sequences, reformatted for axial and coronal projections, passing through the IAC. IH and CM patients were evaluated for tonsillar descent, sagging of the brain, subdural fluid collection, meningeal enhancement and venous engorgement, according to previous MRI studies on IH and CM [12,14,15,18,23,39,42].

## Statistical analysis

BAEP findings in all groups were compared by means of analysis of variance (ANOVA) with Bonferroni correction. Specifically, the latencies of the first, second and third component and the relative interpeaks were compared among control, IH and CM group. The latencies of the V component were compared among all groups (control, IH, CM and SNHL). Test retest variability in controls vs. pre- and post-recovery condition in IH group was compared by paired *t*-test. The efficacy of the latencies of waves I, II, III and V and the interpeak of wave I—III and III—V in separating IH from controls, CM and SNHL groups was evaluated by means of receiver operating characteristic (ROC) curves. Sensitivity, specificity, positive predictive values (PPV) and negative predictive values (NPV) were also performed for each wave and for the interpeak latencies.

## Results

Eighteen patients (43 ± 3 years old, 12 females) were referred to the Neurology Clinics of the University G. d'Annunzio of Chieti-Pescara (Italy) from 2012 to 2017, due to the appearance of one or a combination of the following symptoms: orthostatic headache, chronic headache, hearing loss, tinnitus or acoustic misperception and stupor. The main baseline characteristics of the study patients (symptoms, etiology, treatment protocols) are summarized in Table 1. Table 2 reports auditory thresholds in IH, CM and SNHL groups.

Fifty-two age-matched healthy controls (44 ± 3 years old, 26 males) were selected from our normative population.

From our diagnostic archives we selected eighteen CM patients (49 ± 11 years old, 12 males) without IH and 20 patients with bilateral SNHL (43 ± 10 years old, 10 males) to intermediate- and high-frequency stimuli (28—65 dB loss) due to cochlear pathology.

Table 3 reports BAEP mean latencies of wave I, II, III, V in controls, IH, CM and SNHL. The table reports mean latencies values after recovery in IH, test retest variability in controls and BAEP changes observed in IH after recovery. The table reports also the percentages of delayed (as compared to the mean latencies plus 3 standard deviations of the control group) or absent BAEP components.

Delayed wave I, with latencies above 2 ms was observed in 14 IH patients (78%), in none of CM and in none of SNHL patients. In 3 patients with IH (17%), but also 2 patients with CM (11%) and 14 patients with SNHL (70%) wave I was absent. In two IH patients (11%) the latency of wave I was inside upper latency limits of controls. Delayed wave I in IH was bilateral in 65% and unilateral in 12% of patients.

Delayed wave II was observed in one IH patient. Wave II was absent in 2 IH patients and in 12 SNHL patients. In IH patients the absence of wave II was always combined with the absence of wave I. In 11 SNHL patients the absence of wave II was combined with the absence of wave I and III. In 1 SNHL patient wave II was absent in combination with wave V.

Delayed wave III was observed in 3 IH patients and one CM patient. Wave III was observed only in 7 SNHL patients.

**Table 1** Symptoms, etiology, percentage of recovery due to treatment in IH patients.

| | % of patients |
|---|---|
| Symptoms | |
| Orthostatic headache | 100 |
| Chronic headache | 89 |
| Confusion | 22 |
| Lethargy | 22 |
| Tinnitus | 78 |
| Hearing loss | 78 |
| Hearing changes (alteration in the quality of sounds, i.e. metallic) | 56 |
| Neck stiffness | 56 |
| Etiology | |
| Trauma | 50 |
| Spontaneous (no apparent cause) | 33 |
| After epidural anesthesia | 11 |
| Marfan syndrome, with trauma | 6 |
| Treatment | |
| Bed rest (10—45 days) + hydration | 56 |
| Epidural blood patching (after 7—14 days) | 33 |

IH: intracranial hypotension. IH symptoms had been present for 48—750 days before diagnosis. In 12 patients, IH recovered spontaneously with bed rest and hydration in 10—45 days. Six patients were treated with epidural blood patching (and bed rest) and recovered in 7—14 days.

**Table 2** Auditory threshold (dB) in IH, CM and SNHL groups.

| | Auditory threshold (dB) | | |
|---|---|---|---|
| | 20—30 | 35—50 | > 50 |
| IH | 16 | 2 | None |
| CM | 18 | None | None |
| SNHL | 4 | 7 | 9 |

Auditory thresholds were derived from clicks delivered at a stimulus rate of 10 Hz.
IH: intracranial hypotension; CM: Chiari malformation; SNHL: sensorineural hearing loss.

**Table 3** Mean latencies of BAEP waves I, III and V in controls, IH, CM and SNHL patients. Test retest variability in controls and BAEP changes observed in IH after recovery.

| | I | II | III | V |
|---|---|---|---|---|
| Controls ($n = 52$) | | | | |
| Mean latency ± SD | 1.58 ± 0.11 ($n = 52$) | 2.47 ± 0.14 ($n = 52$) | 3.59 ± 0.12 ($n = 52$) | 5.61 ± 0.13 ($n = 52$) |
| 3 SD upper latency limit | 1.91 | 2.89 | 3.95 | 6.00 |
| Test/retest latency change | ± 0.11 | ± 0.14 | ± 0.12 | ± 0.12 |
| IH ($n = 18$) | | | | |
| Mean latency ± SD | 2.02 ± 0.13 ($n = 15$) | 2.50 + 0.13 ($n = 16$) | 3.72 ± 0.16 ($n = 18$) | 5.93 ± 0.10 ($n = 18$) |
| Delayed (D)/absent (A) % | D 77.8%/A 16.7% | D 5.5%/A 11.1% | D 16.7%/A None | D 27.8%/A None |
| IH post-recovery | | | | |
| Mean latency ± SD | 1.65 ± 0.11 ($n = 18$) | 2.46 ± 0.14 ($n = 18$) | 3.65 ± 0.12 ($n = 18$) | 5.63 ± 0.12 ($n = 18$) |
| Delayed (D)/absent (A) % | D None/A None | D None/A None | D None/A None | D None/A None |
| Latency changes (range) | −0.28 to 0.56 | +0.1 to 0.12 | +0.1 to 0.32 | −0.1 to 0.52 |
| CM ($n = 18$) | | | | |
| Mean latency ± SD | 1.57 ± 0.11 ($n = 16$) | 2.47 ± 0.12 ($n = 18$) | 3.79 ± 0.12 ($n = 18$) | 5.90 ± 0.08 ($n = 18$) |
| Delayed (D)/absent (A) % | D None/A 11.1% | D None/A None | D 5.5%/A None | D 33.3%/A None |
| SNHL ($n = 20$) | | | | |
| Mean latency ± SD | 1.49 ± 0.14 ($n = 6$) | 2.45 ± 0.07 ($n = 8$) | 3.58 ± 0.07 ($n = 7$) | 5.92 ± 0.10 ($n = 19$) |
| Delayed (D)/absent (A) % | D None/A 70% | D None/A 60% | D None/A 65% | D 20%/A 5% |

BAEP: brainstem acoustic evoked potentials. Waves were reported as delayed if the latencies were higher than the mean plus 3 standard deviations of the control groups. The latencies of the wave II were not different significantly among groups.
IH: intracranial hypotension; CM: Chiari malformation; SNHL: sensorineural hearing loss.

In SNHL patients the absence of wave III was combined with the absence of wave I and II in 12 patients.

Delayed wave V was observed in 5 IH patients (28%), in 6 CM patients (33%), and 4 SNHL patients (20%). Wave V was absent only in one SNHL patient.

Ninety-four percent of IH patients presented with, at least, one BAEP abnormality vs. 33% of CM and 70% of SNHL patients.

The latency of wave I, III and wave V was significantly different among groups [F (2,80) = 94.3, $P < 10^{-5}$; F(2,85) = 17.8, $P < 10^{-5}$; F(3,103) = 68.2, $P < 10^{-5}$]. Wave I was delayed in IH compared to controls and CM ($P < 10^{-5}$, for both comparisons). Wave III was delayed in IH ($P = 0.001$) and CM ($P < 10^{-5}$) as compared to controls. Wave V was delayed in IH, CM and SNHL as compared to controls ($P < 10^{-5}$, for all comparisons).

The interpeak latency of wave I—III and III—V was significantly different among groups [F (2,80) = 118.1, $P < 10^{-5}$; F(2,85) = 23.1, $P < 10^{-5}$]. The interpeak latency of wave I—III was lower in IH compared to controls and CM ($P < 10^{-5}$, for both comparisons) and it was higher in CM compared to controls ($P < 10^{-5}$). The interpeak latency of wave III—V was higher in IH compared to controls ($P < 10^{-5}$) and to CM ($P < 0.03$) and it was higher in CM compared to controls ($P < 0.004$).

In IH patients the latencies of wave I and V were reduced after recovery ($P < 0.00001$) and returned inside normal limits (Table 3).

The analysis of BAEP variables shows that abnormalities observed in IH could be summarized by two patterns. One pattern (Fig. 1, top) consisted of delayed wave I with either normal or delayed latency of the subsequent components. The latency of wave I and all subsequent components normalized after recovery (Fig. 1, bottom). Wave II could be absent in control subjects [1]. Thus, the absence of wave II is not usually ascribed to a pathological condition.

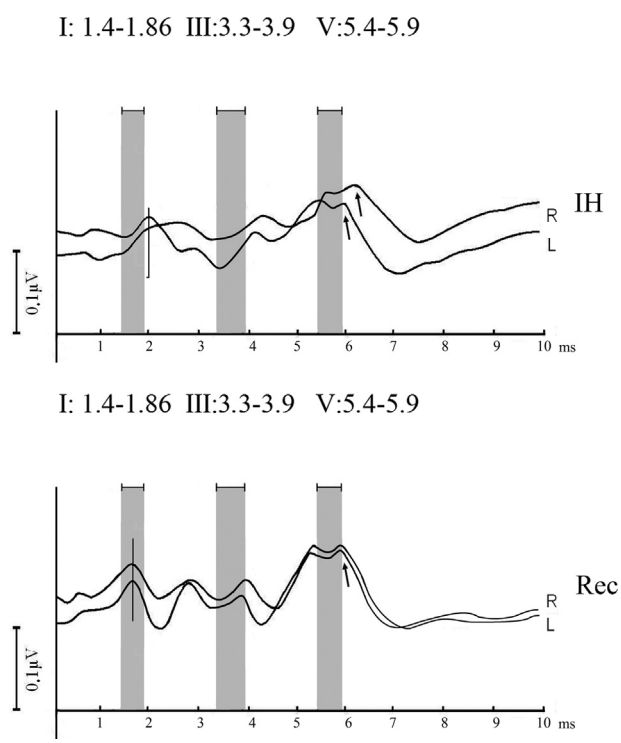


**Figure 1** Patterns of brainstem acoustic evoked potentials (BAEP) abnormalities in intracranial hypotension (IH). Vertical bands indicate latency ranges of components I, III and V in controls. Top: bilateral delayed wave I with delayed wave III—V during IH status (IH). Arrows point to delayed wave V. Bottom: latency delay reduction after recovery (Rec). Arrow points to normalized wave V latency. The vertical line marks wave I latency, which is in the normal range after recovery.

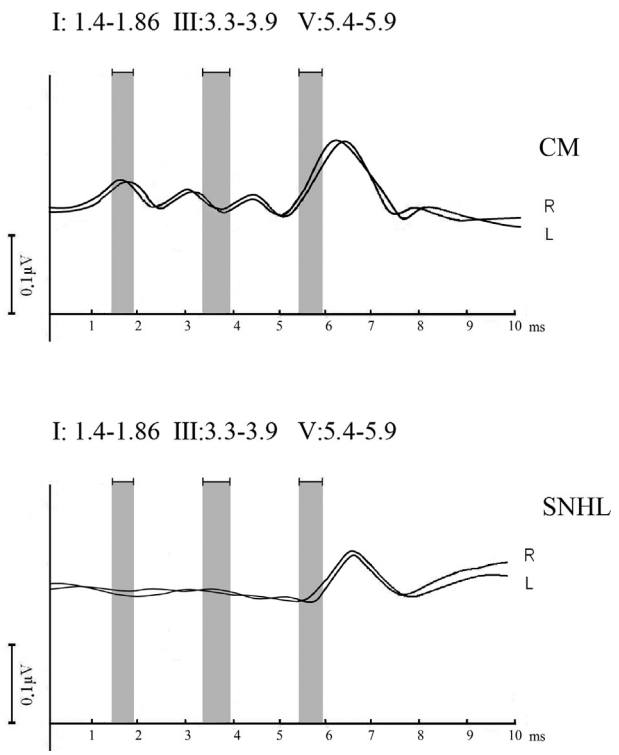


**Figure 2** Patterns of brainstem acoustic evoked potentials (BAEP) abnormalities in Chiari malformation (CM) and sensorineural hearing loss (SNHL). Top: bilateral delayed wave III and V with normal wave I in a patient affected by CM. Bottom: absent wave I and III, and delayed wave V in a SNHL patient. Vertical bars indicate latency ranges of component I, III, V in controls.

A second pattern consisted of absent wave I (and/or II) and delayed wave III—V (Fig. 2, bottom): after recovery wave I reappeared, and the latency of waves III and V was significantly reduced. The first pattern was found (bilaterally) in 77.8% of patients, the second one in 16.7%.

In all IH patients, including the two whose wave I latencies were inside upper limits, recovery was accompanied by latency reduction (Table 3).

The second described pattern was observed also in SNHL and CM patients, accompanied by abnormalities of wave III and interpeak measurements (Fig. 2).

We observed hearing dysfunction on BAEP in 17 patients (delayed or absent wave I) and on MRI in 16 patients (89% T2 hyperintensity of 8th nerve).

Fourteen patients had hearing loss. Among them, all presented both BAEP (delayed or absent wave I) and MRI T2 hyperintensity of 8th nerve.

ROC analysis showed the highest AUC values (93%) for the latency of wave I with 96% specificity and 93% sensitivity in IH. Fig. 3 represents ROC curves for BAEP variables.

Sensitivity, specificity, ROC and PPV/NPV for the cut-off values for each wave and for the interpeak of wave I—III and III—V are reported in Table 4.

MRI evaluation showed that all IH patients presented with one or more typical MRI signs (see Table 5 and Fig. 4). More than 70% of IH patients showed signs of venous distension, pituitary gland hyperemia, pachymeningeal enhancement, tonsillar descent and auditory internal canal abnormalities; closed peduncle-pons angle, engorgement of venous sinuses and stretching of the vein of Galen were present in more than 60% of our cohort of IH patients. Finally, in 56% of cases we reported subdural effusion.

Classic MRI signs of IH were observed in 33—78% of IH patients; the 8th nerve T2 hyperintensity, with contrast enhancement in T1 sequences had the highest frequency (being present in 89% of the IH patients, Table 5, Fig. 5).

Descent of the brain on midsagittal images was shown in Fig. 4A—B. Axial SPAIR and axial and coronal reformatted post-contrast 3D FFE sequences passing through the IAC revealed the presence of linear hyperintense signal along the walls of the IAC (Fig. 5A—B), indicative of the extension of the subdural effusion with narrowing of canal and compression on the seventh and eighth cranial nerve complex.

## Discussion

This study points out how IH can be effectively distinguished from CM and SNHL through the contribution of neurophysiology and MRI. We supposed that hearing alterations might be detected through the combined use of BAEP recordings and MRI sequences focusing on IAC.

Hearing alterations (ranging from misperception to severe hearing loss) are clinical symptoms of IH [14,15,18,39,42]. The mechanism is thought to involve secondary perilymph depression due to patency of the cochlear aqueduct. This induces a compensatory expansion of the endolymphatic compartment with a consequent decrease of basilar or Reissner's membrane compliance [29,38].

Our previous study investigated whether these abnormalities of internal ear or 8th cranial nerve could be tracked by BAEP or IAC MRI [25]. MRI of IAC provided high diagnostic yields in the present and in previous studies [12,18,42]. Our SPAIR protocol showed signs of IAC subdural effusion in 89% IH patients, compared to a 78% best yield provided by the standard MRI assessments of IH, as reported in the previous literature [12,18,42], addressing the different MRI signs for the diagnosis of IH. The high diagnostic yield obtained with SPAIR and post-contrast MRI in our patient suggests that assessment of IH can benefit from both MRI and neurophysiological evaluations of IAC and auditory pathways.

Concerning neurophysiological assessment of brainstem acoustic pathways, we found further evidence of acoustic pathways involvement in IH. Notably, we found a particular pattern of BAEP abnormality in 14 out of 18 IH patients: this pattern, (Fig. 1, top), consisted of delayed wave I with normal latency (or less frequently delay) of the subsequent components. This pattern was not observed in CM or SNHL patients. The wide, albeit old, literature on BAEP in different diseases, has never described selective delayed wave I in disorders involving brainstem or acoustic nerve alterations [17,28]. Absent wave I, or absent waves I, II and III are described in SNHL [27], whereas increased interpeak latencies are described in CM [17]. Delayed wave I is only described when pure tones or low intensity clicks are applied [2], these being in contrast to the high intensity 90 dB click used for diagnostic purposes in neurologic diseases [11].

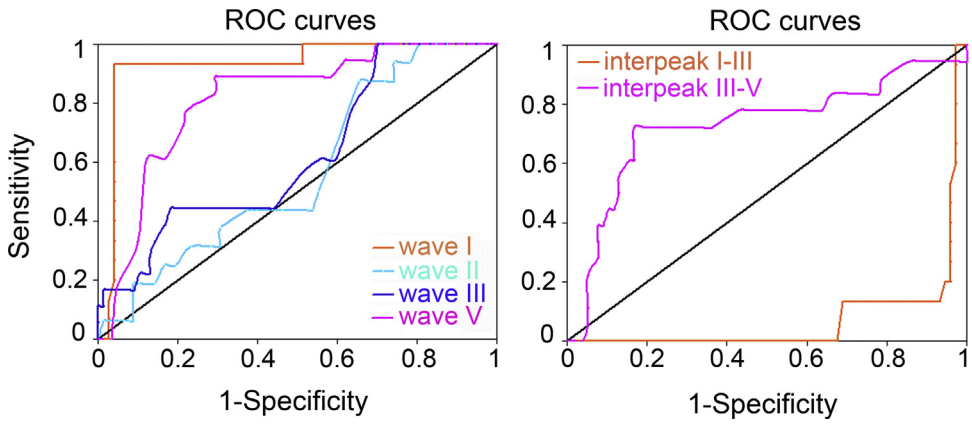


**Figure 3** Receiver operating characteristic (ROC) curves for the latencies of wave I, II, III, V and for the interpeak latencies of wave I—III and III—V.

**Table 4** ROC analysis on the ability of the BAEP wave latencies to distinguish IH patients from controls, CM and SNHL patients.

| Cut-off values | AUC (%) | Sens (%) | Spec (%) | PPV (%) | NPV (%) |
|---|---|---|---|---|---|
| Wave I latency > 1.9 | 93 | 93 | 96 | 82 | 99 |
| Wave II latency > 2.4 | 57 | 88 | 35 | 22 | 93 |
| Wave III latency > 3.6 | 62 | 100 | 30 | 25 | 100 |
| Wave V latency > 5.9 | 81 | 89 | 71 | 38 | 97 |
| Interpeak I—III latency > 1.4 | 7 | 100 | 3 | 17 | 100 |
| Interpeak III—V latency > 2.1 | 73 | 72 | 83 | 50 | 93 |

ROC: receiver operating characteristic; BAEP: brainstem acoustic evoked potentials; IH: intracranial hypotension; CM: Chiari malformation; SNHL: sensorineural hearing loss; AUC: area under the ROC curve; NPV: negative positive values; PPV: positive predictive values; Sens: sensitivity; Spec: specificity.

**Table 5** 3T IAC MRI finding in IH patients.

| MRI findings in IH | % |
|---|---|
| Auditory internal canal abnormalities (T2 hyperintensity or/and contrast enhancement of the 8th cranial nerve) | 89 (11 unilateral) |
| Venous distension sign | 78 |
| Pituitary gland hyperemia | 78 |
| Tonsillar descent | 72 |
| Pachymeningeal enhancement | 72 |
| Closed peduncle-pons angle | 67[a] |
| Engorgement of venous sinuses | 67[a] |
| Stretching of the vein of Galen | 67[a] |
| Subdural effusions | 56[b] |
| Ponto-mesencephalic sag-ratio | 33[c] |

IH: intracranial hypotension; MRI: magnetic resonance imaging. Statistical comparisons between the percentage of patients showing auditory internal canal MRI abnormalities and the percentage of patients showing other MRI findings yielded significant results for [a], [b] and [c] comparisons.
[a] $Chi^2 = 4.8$, $P = 0.03$.
[b] $Chi^2 = 7.8$, $P = 0.005$.
[c] $Chi^2 = 15.8$, $P = 0.001$

A second pattern of BAEP abnormality, with absent wave I or delayed or small amplitude wave V, was also observed in 3 of 18 patients with IH, but was not specific, as it was also found in CM and SNHL patients (Fig. 2), consistent with earlier literature reports [17,20,27]. In all IH patients, after recovery, waves I and V reappeared and the latencies were in the normal range. Our study suggests, therefore, that BAEP recordings can constitute a non-invasive and inexpensive tool to monitor IH course.

BAEP were initially thought to be generated by electrical activities arising in the cochlear and other brainstem nuclei of the acoustic pathway (8th nerve, lateral lemniscus,

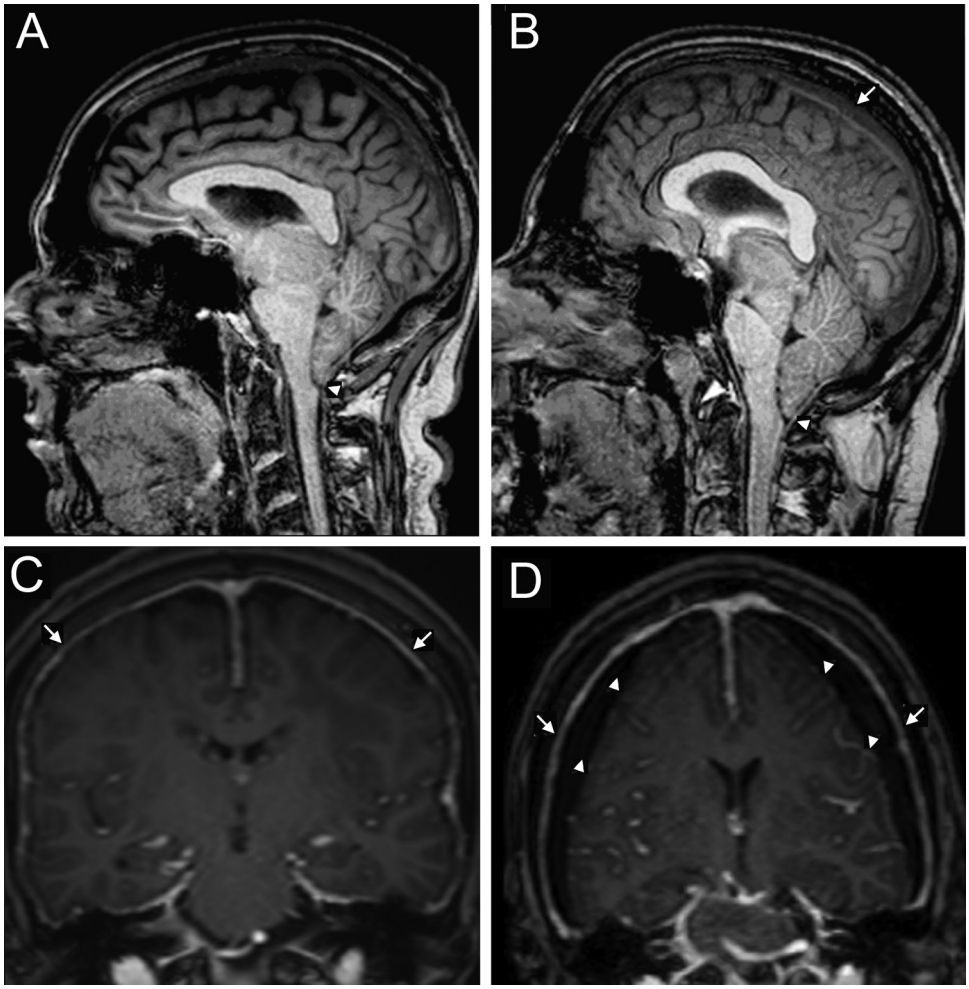


**Figure 4** Magnetic resonance imaging (MRI) findings in patients with Chiari malformation (CM) and intracranial hypotension (IH). Sagittal 3D T1-weighted FFE sequence demonstrates descent of the brainstem and the cerebellum through the posterior cranial fossa and the occipital canal (white triangle) in a CM (A) and IH (B). To note the narrowing of the cisternal spaces, cerebellar tonsillar herniation and subdural effusions in IH (white arrow, B). Post-contrast axial T1-weighted images of two IH patients showing hyperintense leptomeningeal signal (white arrows, C—D) and bilateral subdural effusion (white triangles, D).

superior olivary nuclei) and as such they are still described in recent studies and handbooks [34]. However, refinement of electric field distribution theories later evidenced that brainstem nuclei, being closed fields, cannot generate far-field evoked potentials, such as BAEP early waves I—V, and that the model was erroneous [20]. BAEP far-field waves are rather generated by conductance changes or angular displacement of the linear quadrupole, which is the representation of the travelling afferent volley of impulses in a myelinated pathway[21,28]. Based on this representation [21,28], we hypothesize that BAEP wave I delay should not be attributed to cochlear abnormalities, but to changes in conductance due to endolymphatic expansion and to changes of the 8th cranial nerve cochlear exit conformation.

## Conclusions and limitations

BAEP abnormalities observed in IH patients could be summarized by two patterns. The first pattern was found in 77.8% of patients and consisted of bilateral delayed wave I with either normal or delayed latency of the subsequent components. A second pattern consisted of absent wave I and delayed wave III—V: this pattern occurred in 16.7% of IH patients and might overlap with CM and SNHL. IH patients presented typical MRI signs, but the 8th nerve T2 hyperintensity, with contrast enhancement in T1 sequences was present in 89% of the IH patients and sequences passing through the IAC revealed the presence of linear hyperintense signal along the walls of the IAC.

It would be interesting to find out the potential additive value of BAEP in cases with inconclusive MRI. Interestingly, our data support the idea that BAEP and MRI T2 hyperintensity of 8th nerve both occur before hearing loss. Among our 18 patients with IH, two patients presented positive spinal MRI, but without T2 hyperintensity of 8th nerve on brain MRI. One patient had BAEP abnormalities (delayed wave I), in absence of T2 hyperintensity of 8th nerve, whereas the other had normal BAEP. However, in our study there was only one patient in whom BAEP abnormalities preceded MRI alterations. In addition, we enrolled only patients with

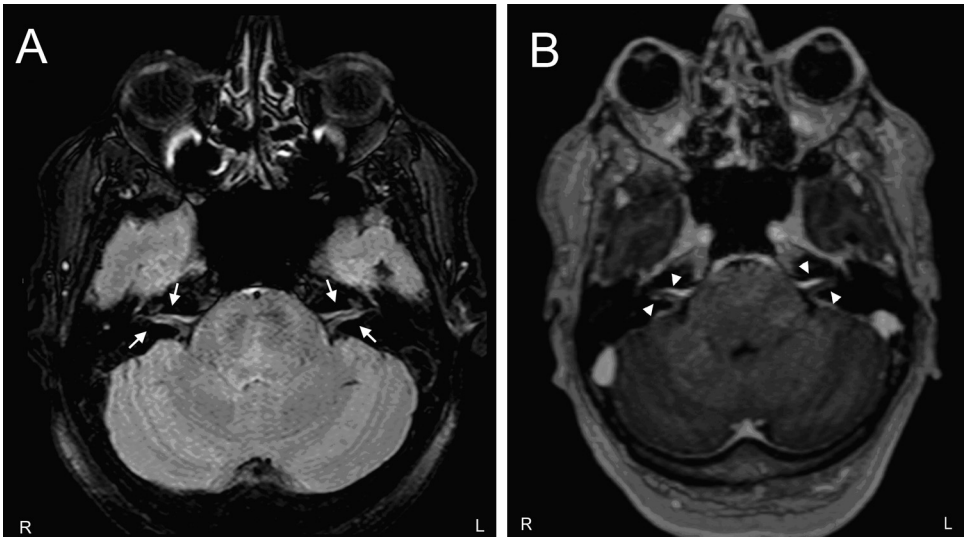


**Figure 5** Magnetic resonance imaging (MRI) findings in a patient with intracranial hypotension (IH). Axial SPAIR image passing through the IAC shows linear hyperintense signal within the bilateral IAC indicative of subdural effusion (white arrows, A). Post-contrast axial reformatted 3D T1-weighted image passing through the IAC shows linear enhancement along the walls of the IAC bilaterally (white triangles, B).

a diagnosis confirmed by spinal MRI and none, among our included patients, had inconclusive neuroimaging results, presenting further associated signs, i.e. subdural effusion, the venous distension sign, etc. Further studies are needed to establish the predictive value of BAEP in cases with inconclusive MRI findings.

Our results indicate that combined use of BAEP and MRI can be useful in the differential diagnosis of IH. However, the results are far from being conclusive, because of some important technical limitations.

The first limitation of this study is the use of the alternating click, which is a delivery of a rarefaction click followed by a condensation click. The alternating stimulus polarity may cause phase cancellation and distortion of wave I; thus the abnormality found on wave I might actually be due to the aforementioned suboptimal stimulation technique. In addition, in some pathological conditions associated with high-frequency hearing loss, BAEP elicited by rarefaction clicks may differ in latency from BAEP evoked by condensation clicks [9]. Thus, the delayed latencies obtained from clicks of alternating polarity cannot be ascribed to rarefaction or condensation. Nevertheless, alternating click polarity is the most commonly used polarity in the operating room, because it decreases stimulation artifact and eliminates cochlear microphonic, a receptor potential believed to be generated primarily by outer hair cells [37]. The removal of the cochlear microphonic is important, because it can bleed over wave I, especially when high intensities are used, making it unreliable. In addition, in the present study, the use of an external ear canal supplementary electrode, as well as slow stimulation rates (10 Hz), could help to preserve wave I morphology. Further studies should use rarefaction and condensation stimuli separately to confirm our results. The second limitation of this study is that we did not collect data on pattern of hearing loss in patients who did not perform a pure tone audiometry. Thus, patterns of hearing loss were not matched between IH patients and the other groups of patients. We are aware that conductive hearing loss might affect waveforms latencies. But, as hypoacusia was a symptom in IH patients, it is possible that differences in BAEP alterations could be associated with differences of patterns of hearing loss, especially in SNHL patients. Further studies should investigate BAEP alterations in patients with different patterns of hearing loss. Further prospective studies are mandatory to confirm our data on larger populations of IH patients.

## Funding

This research did not receive any specific grant from funding agencies in the public, commercial, or not-for-profit sectors.

## Disclosure of interest

Prof. Marco Onofrj has served on the scientific advisory boards of GlaxoSmithKline, Novartis, Lundbeck, Eisai, Valeant, Medtronic, and Newron; has received speaker honoraria from Zambon, the World Parkinson Congress, the Movement Disorder Society, and the Atypical Dementias congress; was an invited guest and lecturer for the Mental Disorders in Parkinson Disease Congress; serves on the editorial board of Medicine (Baltimore); has been employed as a speaker for Boehringer Ingelheim, GlaxoSmithKline, UCB, and Zambon; and has received research support from the Italian Ministry of Health and the Italian Ministry of Education. Prof. Laura Bonanni served as an editorial board member for *Journal of Alzheimer's disease*. Dr. Vincenzo Di Stefano, Dr. Camilla Ferrante, Dr. Roberta Telese, Dr. Raffaella Franciotti and Prof. Massimo Caulo declare that they have no competing interest.

## Acknowledgements

The authors would like to thank Dr. Nanni Stefania and Dr. Saracino Antonio (Department of Neurology, ''SS. Annunziata'' Hospital of Chieti) for neurophysiopathology technical support.

## Références

[1] American Clinical Neurophysiology Society. Guideline 9C: guidelines on short-latency auditory evoked potentials. J Clin Neurophysiol 2006;23:157—67.
[2] Burkard R, Hecox K. The effects of broadband noise on the human brainstem auditory evoked response. I. Rate and intensity effects. J Acoust Soc Am 1983;74:1204—13.
[3] Chiappa KH, Gladstone KJ, Young RR. Brainstem audiroty evoked responses: studies of waveform variations in 50 normal human subjects. Arch Neurol 1979;36:81—7.
[4] Chiappa KH. Pattern schift visual, brainstem auditory and short-latency somatosensory evoked potentials in multiple sclerosis. Neurology 1980;30:110—23.
[5] Chiappa KH, Harrison JL, Brooks EB, Young RR. Brainstem auditory evoked responses in 200 patients with multiple sclerosis. Ann Neurol 1980;7:135—43.
[6] Chiappa KH. Evoked potential in clinical medicine. 3rd ed. Philadelphia: Lippincott-Raven; 1997. p. 31—130.
[7] Chisin R, Gafni M, Sohmer H. Patterns of auditory nerve and brainstem evoked responses (ABR) in different types of peripheral hearing loss. Arch Otolaryngol 1983;237:165—75.
[8] Coats AC, Martin JL. Human auditory nerve action potentials and brain stem evoked responses: effects of audiogram shape and lesion location. Arch Otolaryngol 1977;103: 605—22.
[9] Coats AC. Human auditory nerve action potential and brain stem evoked responses. Arch Otolaryngol 1979;104:709—17.
[10] Don M, Allen AR, Starr A. Effect of click rate on latency of auditory brainstem responses in humans. Ann Oto Rhinol Laryngol 1977;86:186—95.
[11] Eggermont JJ, Don M. Analysis of the click-evoked brainstem potentials in humans using high-pass noise masking. II. Effect of click intensity. J Acoust Soc Am 1980;68:1671—5.
[12] Farb RI, Forghani R, Lee SK, Mikulis DJ, Agid R. The venous distension sign: a diagnostic sign of intracranial hypotension at MR imaging of the brain. AJNR Am J Neuroradiol 2007;28: 1489—93.
[13] Ferrante E, Regna-Gladin C, Citterio A, Arpino I. Spontaneous intracranial hypotension syndrome with hearing loss and pachymeningeal enhancement in the internal acoustic canal: neuroimaging correlations. J Craniofac Surg 2010;21: 1660—1.
[14] Franzini A, Messina G, Nazzi V, Mea E, Leone M, Chiapparini L, et al. Spontaneous intracranial hypotension syndrome: a novel speculative physiopathological hypothesis and a novel patch method in a series of 28 consecutive patients. J Neurosurg 2010;112:300—6.
[15] Headache Classification Committee of the International Headache Society (IHS). The International Classification of Headache Disorders. 3rd edition. Cephalalgia 2018;38: 1—211.
[16] Hecox K, Squires N, Galambos R. Brainstem auditory evoked responses in man effect of stimulus rise-fall time and duration. J Acous Soc Am 1976;60:1187—92.
[17] Henriques Filho PS, Pratesi R. Abnormality in auditory evoked potential of 75 patients with Arnold—Chiari malformations types I and II. Arq Neuropsiquiatr 2006;64:619—23.
[18] Hori S, Taoka T, Miyasaka T, Ochi T, Sakamoto M, Wada T, et al. Dural thickening of the internal auditory canal in patients with spontaneous intracranial hypotension syndrome. J Comput Assist Tomogr 2016;40:297—300.
[19] Jewett DL. The leading/trailing Dipole model as a means of understanding generators of far-field potentials. Clin Evoked Potentials 1989;7:9—13.
[20] Jewett DL, Deupree DL. Far-field potentials recorded from action potentials and from a tripole in a hemicylindrical volume. Electroencephalogr Clin Neurophysiol 1989;72:439—49.
[21] Kimura J, Ishida T, Suzuki S, Kudo Y, Matsuoka H, Yamada T. Far-field recording of the junctional potential generated by median nerve volleys at the wrist. Neurology 1986;36: 1451—7.
[22] Kjaer M. Variations of brainstem auditory evoked potentials correlated to duration and severity of multiple sclerosis. Acta Neurol Scand 1980;61:157—66.
[23] McVige JW, Leonardo J. Neuroimaging and the clinical manifestations of Chiari malformation type I (CMI). Curr Pain Headache Rep 2015;19:18.
[24] Onofrj M, D'Annunzio V, Mangiola A. I potenziali evocati acustici del tronco dell'encefalo in patologia neurochirurgica. Riv It EEG Neurof Clin 1984;7:425—8.
[25] Onofrj M, Franciotti R, Di Stefano V, Cioffi E, Caulo M, Bonanni L. Abnormal BAEP and internal auditory canal MRI in intracranial hypotension. J Neurol Neurosurg Psychiatry 2018;89:437—9.
[26] Paludetti G, Maurizi M, Ottaviani F. Effect of stimulus repetition rate on the auditory brainstem responses (ABR). Am J Otol 1983;3:226—34.
[27] Paulraj MP, Subramaniam K, Yaccob SB, Adom AH, Hema CR. Auditory evoked potential response and hearing loss: a review. Open Biomed Eng J 2015;9:17—24.
[28] Picton TW, Stapells DR, Campbell KB. Auditory evoked potentials from the human cochlea and brainstem. J Otolaryngol 1981;10:1—41.
[29] Portier F, de Minteguiaga C, Racy E, Huy PT, Herman P. Spontaneous intracranial hypotension: a rare cause of labyrinthine hydrops. Ann Otol Rhinol Laryngol 2002;111:817—20.
[30] Pratt H, Sohmer H. Comparison of hearing threshold determined by auditory pathway electric responses and by behavioral responses. Audiology 1978;17:285—92.
[31] Prosser S, Arslan E, Conti G, Michelini S. Evaluation of the monoaurally evoked brainstem response in diagnosis of sensory-neural hearing loss. Scand Audiol 1983;12:103.
[32] Rabin BM, Roychowdhury S, Meyer JR, Cohen BA, LaPat KD, Russell EJ. Spontaneous intracranial hypotension: spinal MR findings. AJNR Am J Neuroradiol 1998;19:1034—9.
[33] Robinson K, Rudge P. Abnormalities of the auditory evoked potentials in normal men and patients with multiple sclerosis. Brain 1977;100:19—40.
[34] Ropper AH, Samuels MA, Klein J. Adams and Victor's principles of neurology. 10th ed. New York: McGraw-Hill Education Medical; 2014. p. 36.
[35] Rosenhammer HJ. Observation on electric brainstem responses in retrococlear hearing loss. Scand Audiol 1977;6:179—96.
[36] Rossini PM, Onofrj M, Gambi D, Sollazzo D, Lo Monaco M. Il potenziale evocato acustico troncoencefalico in soggetti normali a diverse età. Riv It EEG Neurof Clin 1979;11: 527—9.
[37] Santarelli R, Scimemi P, Dal Monte E, Arslan E. Cochlear microphonic potential recorded by transtympanic electrocochleography in normally-hearing and hearing-impaired ears. Acta Otorhinolaryngol Ital 2006;26:78—95.
[38] Schievink WI, Maya MM, Moser F, Tourje J, Torbati S. Frequency of spontaneous intracranial hypotension in the emergency department. J Headache Pain 2007;8:325—8.

[39] Schievink WI, Smith KA. Non-positional headache caused by spontaneous intracranial hypotension. Neurology 1998;51:1768—9.
[40] Schievink WI, Maya MM, Moser FG, Jean-Pierre S, Nuño M. Coma: a serious complication of spontaneous intracranial hypotension. Neurology 2018;90:1638—45.
[41] Stockard JJ, Stockard JE, Sharbrough FW. Nonpatologic factors influencing brainstem auditory evoked potentials. Am J EEG Technol 1978;18:177—209.
[42] Urbach H. Intracranial hypotension: clinical presentation, imaging findings, and imaging-guided therapy. Curr Opin Neurol 2014;27:414—24.