



# Detection of Osteomyelitis in the Diabetic Foot by Imaging Techniques: A Systematic Review and Meta-analysis Comparing MRI, White Blood Cell Scintigraphy, and FDG-PET

*Diabetes Care* 2017;40:1111–1120 | <https://doi.org/10.2337/dc17-0532>

Chiara Lauri,<sup>1,2</sup> Menno Tamminga,<sup>1</sup>  
Andor W.J.M. Glaudemans,<sup>1</sup>  
Luis Eduardo Juárez Orozco,<sup>1</sup>  
Paola A. Erba,<sup>3</sup> Paul C. Jutte,<sup>4</sup>  
Benjamin A. Lipsky,<sup>5,6</sup>  
Maarten J. IJzerman,<sup>7</sup> Alberto Signore,<sup>1,2</sup>  
and Riemer H.J.A. Slart<sup>1,8</sup>

## OBJECTIVE

Diagnosing bone infection in the diabetic foot is challenging and often requires several diagnostic procedures, including advanced imaging. We compared the diagnostic performances of MRI, radiolabeled white blood cell (WBC) scintigraphy (either with <sup>99m</sup>Tc-hexamethylpropyleneamineoxime [HMPAO] or <sup>111</sup>In-oxine), and [<sup>18</sup>F]fluorodeoxyglucose positron emission tomography (<sup>18</sup>F-FDG-PET)/computed tomography.

## RESEARCH DESIGN AND METHODS

We searched Medline and Embase as of August 2016 for studies of diagnostic tests on patients known or suspected to have diabetes and a foot infection. We performed a systematic review using criteria recommended by the Cochrane Review of a database that included prospective and retrospective diagnostic studies performed on patients with diabetes in whom there was a clinical suspicion of osteomyelitis of the foot. The preferred reference standard was bone biopsy and subsequent pathological (or microbiological) examination.

## RESULTS

Our review found 6,649 articles; 3,894 in Medline and 2,755 in Embase. A total of 27 full articles and 2 posters was selected for inclusion in the analysis. The performance characteristics for the <sup>18</sup>F-FDG-PET were: sensitivity, 89%; specificity, 92%; diagnostic odds ratio (DOR), 95; positive likelihood ratio (LR), 11; and negative LR, 0.11. For WBC scan with <sup>111</sup>In-oxine, the values were: sensitivity, 92%; specificity, 75%; DOR, 34; positive LR, 3.6; and negative LR, 0.1. For WBC scan with <sup>99m</sup>Tc-HMPAO, the values were: sensitivity, 91%; specificity, 92%; DOR, 118; positive LR, 12; and negative LR, 0.1. Finally, for MRI, the values were: sensitivity, 93%; specificity, 75%; DOR, 37; positive LR, 3.66, and negative LR, 0.10.

## CONCLUSIONS

The various modalities have similar sensitivity, but <sup>18</sup>F-FDG-PET and <sup>99m</sup>Tc-HMPAO-labeled WBC scintigraphy offer the highest specificity. Larger prospective studies with a direct comparison among the different imaging techniques are required.

<sup>1</sup>Department of Nuclear Medicine and Molecular Imaging, University of Groningen, University Medical Center Groningen, Groningen, the Netherlands

<sup>2</sup>Nuclear Medicine Unit, Faculty of Medicine and Psychology, Department of Medical-Surgical Sciences and of Translational Medicine, Sapienza University of Rome, Rome, Italy

<sup>3</sup>Department of Nuclear Medicine, University of Pisa, Pisa, Italy

<sup>4</sup>Department of Orthopedics, University of Groningen, University Medical Center Groningen, Groningen, the Netherlands

<sup>5</sup>Division of Medical Sciences, Green Templeton College, University of Oxford, Oxford, U.K.

<sup>6</sup>Department of Medicine, University of Washington, Seattle, WA

<sup>7</sup>Department of Health Technology and Services Research, MIRA Institute for Biomedical Technology & Technical Medicine, University of Twente, Enschede, the Netherlands

<sup>8</sup>Department of Biomedical Photonic Imaging, University of Twente, Enschede, the Netherlands

Corresponding author: Riemer H.J.A. Slart, [r.h.j.a.slart@umcg.nl](mailto:r.h.j.a.slart@umcg.nl).

Received 15 March 2017 and accepted 3 May 2017.

C.L. and M.T. contributed equally to this work.

© 2017 by the American Diabetes Association. Readers may use this article as long as the work is properly cited, the use is educational and not for profit, and the work is not altered. More information is available at <http://www.diabetesjournals.org/content/license>.

Most persons with longstanding diabetes develop peripheral neuropathy that, together with peripheral vascular disease (and microvascular dysfunction), often leads to foot complications. Patients with diabetes with these complications have an ~25% lifetime risk of developing a foot complication (1,2), and these now appear to be the most common diabetes-related reason for hospitalization. At presentation, >50% of diabetic foot wounds are clinically infected (3). Most are initially soft-tissue diabetic foot infections (DFIs), but these often spread contiguously to underlying bone, resulting in diabetic foot osteomyelitis (DFO). DFO is now the most frequent cause of nontraumatic lower-extremity amputations that are associated with a 5-year mortality of ~50% (4). Therefore, prompt identification and optimal treatment of DFO are important to help avoid poor outcomes (5).

Infection in the diabetic foot is defined by the presence of classic signs of inflammation and sometimes so-called “secondary” signs (3). Identifying DFO, which occurs in ~20% of mild infections and >50% of severe cases (3,6,7), can be more difficult. This is related to the fact that: 1) DFO can occur in association with uninfected as well as infected ulcers; 2) radiographic changes in bone may be nonspecific and delayed for a few weeks after infection; and 3) patients with diabetes are also at risk for developing neuroarthropathy of the foot (Charcot foot [8,9]). The approach to treatment depends on proper diagnosis, as DFO usually requires antibiotic and surgical treatment, whereas Charcot disease requires proper offloading, sometimes with later surgical correction. Thus, diagnosing DFO requires a systematic approach that includes clinical, imaging, microbiological, and histopathological methods.

The most widely accepted criterion standard for diagnosing DFO is the presence of characteristic findings on histopathological examination and growth on culture of an aseptically obtained specimen bone (10). Bone biopsy, however, is an invasive procedure, and histology and culture are relatively expensive and time-consuming. Thus, it is important to determine which of the other available diagnostic tests for DFO might be appropriate in selected patients. Clinical examinations, such as the probe-to-bone test (11), inflammatory markers (especially the erythrocyte sedimentation rate)

(12), and plain X-rays are nearly always the first steps in diagnosing DFO. In some cases, however, they fail to provide diagnostic results. In these situations, more advanced imaging techniques are often needed.

Imaging offers a complementary and less invasive, although often expensive, approach to diagnosing DFO, with a wide panel of modalities including: MRI, scintigraphy with  $^{99m}\text{Tc}$ -hexamethylpropyleneamineoxime (HMPAO) or  $^{111}\text{In}$ -oxine-labeled white blood cells ( $^{99m}\text{Tc}$ -HMPAO-WBCs or  $^{111}\text{In}$ -oxine-WBCs) with single-photon emission computed tomography (SPECT/computed tomography [CT]), [ $^{18}\text{F}$ ]fluorodeoxyglucose positron emission tomography ( $^{18}\text{F}$ -FDG-PET/CT), or  $^{99m}\text{Tc}$ -antigranulocyte antibody scintigraphy (13–18). Choosing the most appropriate advanced imaging modality must be based on not only the patient’s clinical presentation but also the equipment and expertise available at the treating center. Key factors include any recent or ongoing antibiotic therapy, the presence of neuropathic disease of the foot, the financial costs of various tests, the waiting time before imaging can be performed, any possible contraindications to the tests, and patient preference and likely adherence.

Of course, another key issue is which of the tests is most diagnostically useful. To determine the performance characteristics of the currently available advanced imaging tests for diagnosing DFO, we performed a systematic review and meta-analysis of the literature. The results of this review should help clinicians and organizations in preparing guidelines for the multimodality approach required for diagnosing DFO.

## RESEARCH DESIGN AND METHODS

We conducted this systematic review in accordance with methods outlined in the Cochrane Handbook for Systematic Reviews of Diagnostic Test Accuracy (19) and have presented it following the Preferred Reporting Items for Systematic Reviews and Meta-analysis (PRISMA) guidelines (20).

### Eligible Studies

We only included studies that: provided original data; were designed to provide information on diagnosis; were conducted in patients known or suspected to have both diabetes (type 1 or 2, regardless of

method of glycemic treatment) and a foot infection; and were published in English. We considered studies for inclusion with either a prospective or retrospective design and blinded or nonblinded. Because of the risk of introducing bias, we excluded case-control studies, case reports, case series, and animal studies. We also excluded: reviews; articles on topics not germane to our study question (e.g., Charcot neuroarthropathy, magnetic resonance angiography for arterial disease, orthopedic implants, inflammatory markers, therapeutic studies, and studies on non-foot infections); articles focused on other index tests or using other less specific radiopharmaceuticals ( $^{67}\text{Ga}$ -citrate, labeled diphosphonates, labeled IgG, labeled ciprofloxacin, or labeled ubiquickidin); and articles that used currently outdated methodologies or protocols.

### Literature Sources and Search

We searched the databases of Medline and Embase for studies published through August 2016. We used a combination of Medical Subject Headings terms and free-text words to define: our population of interest (persons with diabetes); the pathologic process of interest (osteomyelitis or infections of bone); and the specified imaging techniques used (MRI,  $^{111}\text{In}$ -oxine-WBC SPECT/CT,  $^{99m}\text{Tc}$ -HMPAO-WBC SPECT/CT, or  $^{18}\text{F}$ -FDG-PET/CT). No studies with antigranulocyte antibodies could be included, because of the very limited application in diabetic foot diagnostics. Table 1 shows the extended query and complete search terms.

### Screening and Selection of Literature

Three reviewers (C.L., M.T., and R.H.J.A.S.) independently screened all retrieved studies obtained based on their title and abstract. In a subsequent secondary screening, we evaluated the full text of the selected articles for eligibility. We jointly discussed, and resolved by consensus, any discrepancy among the reviewers that arose in study screening and selection. We also conducted a search of the references included in the retrieved articles seeking any additional potentially relevant articles.

### Diagnostic Criterion Standard

Our preferred reference standard for the diagnosis of osteomyelitis (against which we compared the diagnostic performance of the target imaging techniques) was evaluation of a specimen of affected

**Table 1—Search terms used for Medline and Embase**

MeSH terms used for search	Text words used for search
Diabetes mellitus	Diabetic foot
Foot ulcer	Diabetic
Radionuclide imaging	Pedal
Technetium <sup>99m</sup> Tc exametazime	Diabetic patient*
Infection	Diabetes
Tomography	Infect*
Multimodal imaging	Ulcer*
	Inflamm*
	Osteomyelit*
	Imaging
	Tomograph*
	CT
	PET CT
	PETCT
	SPECT
	99m-tc
	Technetium tc 99m
	tc 99m
	99mtc
	MRI
	Leukocyte scan*
	Leukocyte scan*
	Scinti*

Search terms used for finding potential publications in PubMed and Embase. Important search terms are in the field of the diagnostic value of different imaging modalities in the suspected infected diabetic foot. MeSH, Medical Subject Headings. \*Search for all terms beginning with this string of text.

bone (collected by surgical or percutaneous biopsy) by histopathological review and/or culture. We only included studies that used this standard in our pooled estimation of diagnostic performance metrics (sensitivity and specificity). However, as it is common in clinical practice to use follow-up (history and physical examination, blood tests, and plain X-rays) to diagnose osteomyelitis, we also included studies that used this approach for just the calculation of positive and negative predictive values.

#### Data Extraction and Quality Assessment

Two reviewers (M.T. and L.E.J.O.) independently extracted data from each study and evaluated them for quality using the QUADAS-2 method (19). They jointly discussed and resolved any discrepancies by consensus. The domains of interest in standardized data extraction were: population characteristics; imaging methods; reference standard for diagnosing osteomyelitis; descriptive and quantitative results (we generated a two-by-two contingency table for each imaging modality); and frequencies for

final diagnoses (using RevMan v.5 for extraction).

For quality assessment, QUADAS-2 considers four main domains: risk of bias in patient selection (low, high, or unclear); index test; reference test; and, study flow and timing. We assessed the risk of bias and applicability concerns per imaging modality per study, then overall as follows: 1) low, if there was a low risk of bias in all key domains; 2) unclear, if we could not assess the risk of bias in one or more key domains; and 3) high, if the risk of bias was high for one or more key domains (20).

#### Statistical Analysis

We used the STATA program (version 12.1; StataCorp), SPSS v.21 for Windows (IBM), and RevMan 5 for statistical analyses, setting statistical significance at  $P < 0.05$ . Using a hierarchical random effects model for binary data, we calculated a summary estimate of the diagnostic odds ratio (DOR) and 95% CIs per imaging technique. The odds ratio is a measure of effect size, describing the strength of association or nonindependence between two binary data values. The likelihood

ratio (LR) we applied is used for assessing the value of performing the diagnostic imaging tests. The sensitivity and specificity of the test is used to determine whether a test result usefully changes the probability that a condition (such as the state of the diabetic foot, infected or not) exists.

We generated the summary receiver operating characteristic (sROC) curves and documented the sensitivity, specificity, and positive and negative LRs for every index test studied (i.e., MRI, <sup>111</sup>In-oxine-WBC SPECT/CT, <sup>99m</sup>Tc-HMPAO-WBC SPECT/CT, or <sup>18</sup>F-FDG-PET/CT). We assessed statistical heterogeneity among included studies using the  $I^2$  statistic (21,22), which expresses the percentage of the variability that might be because of heterogeneity rather than sampling error.

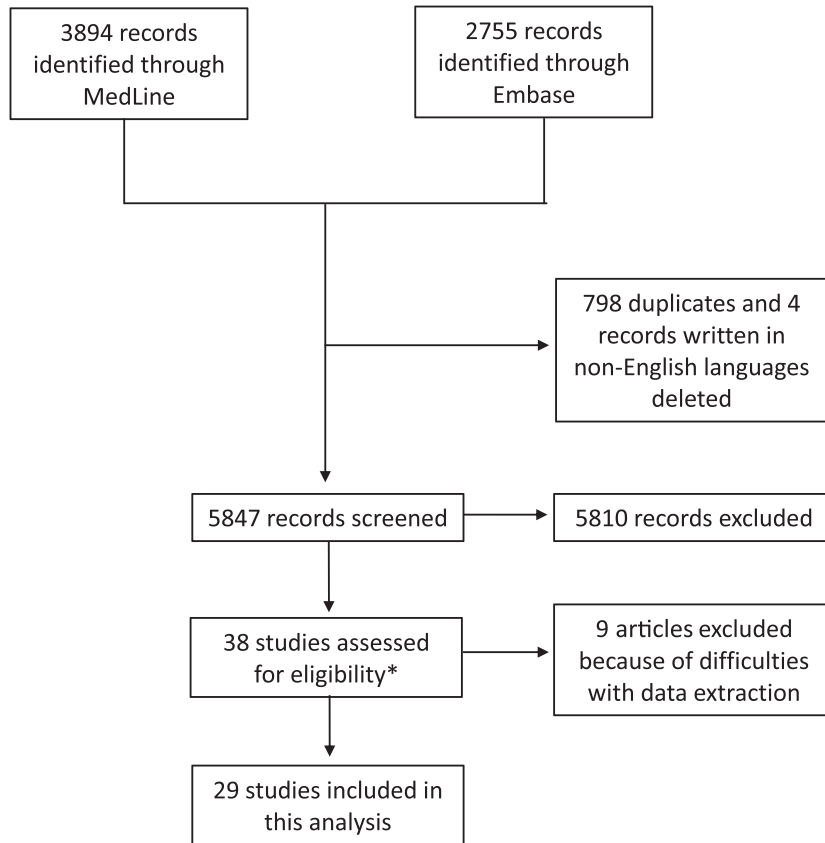
## RESULTS

### Screening and Selection of Literature

Our search of PubMed and Embase identified 3,894 and 2,755 articles, respectively (Fig. 1). After screening each article based on its title and abstract, we assessed the full article for 38 and included 29 studies (23–51) in our meta-analysis. Among these studies, 13 were focused on MRI, 9 on <sup>111</sup>In-oxine-WBC, 10 on <sup>99m</sup>Tc-HMPAO-WBC, and 6 on <sup>18</sup>F-FDG-PET/CT. Two of the included studies were posters for which we could extract the data, but the information was insufficient to allow us to perform a bias assessment. For one of these posters, we obtained additional information from an author and used this to include the study in our meta-analysis.

### Characteristics and Methodological Aspects of the Included Studies

Most of the included studies provided information on the population characteristics and key methodological aspects. Most studies were prospective, but some were retrospective, and some enrolled patients did not undergo all tests. Many included studies used the dual reference standard of clinical follow-up for test-negative patients and bone biopsy with subsequent pathological examination for test-positive patients. Many studies lacked data regarding the use of antibiotic therapy, anti-inflammatory drugs, or control of serum glucose levels. Only one reviewer assessed imaging results in most studies; in those with more



\*Excluded: reviews (no original data); articles on different subjects; articles focused on other index tests or using other radiopharmaceuticals; and articles that used out-dated imaging methodologies or protocols

**Figure 1**—Schematic flow chart explaining the process for selection of articles included in this meta-analysis.

reviewers, the authors rarely provided information regarding interobserver agreement.

In some studies, investigators used different protocols for the several imaging modalities. In most studies, the imaging protocols used did not conform to current standard acquisition procedures, and they were often combined with a bone scan (especially for those using  $^{111}\text{In}$ -oxine-WBC), causing preselection of patients. Most of the WBC studies included in our review used only planar images acquired with fixed, single times and often failed to explain the acquisition protocol. The heterogeneity in imaging protocols of acquisition and interpretation is evident for WBC scan using both  $^{99\text{m}}\text{Tc}$ -HMPAO and  $^{111}\text{In}$ -oxine.

Studies with PET mainly consisted of visual assessment of  $^{18}\text{F}$ -FDG uptake without any semiquantitative analysis

(e.g., measuring the standardized uptake value). For studies using MRI, most scanners were of low magnetic field strength, and, although the articles were often out-dated, they used correct protocols and sequences for identifying infections.

Figures 2 and 3 show the results of our assessment of methodological quality, based on the QUADAS-2 checklist (patient selection, index test, reference standard, flow, and timing) and our assessment on the risk of bias. Because we could not assess the two included posters adequately, we assessed them as unknown (Fig. 2, yellow) for all corresponding domains.

#### Pooled Diagnostic Performance of the Imaging Techniques (Meta-analysis)

For each test, we have combined the sROC curves, and their corresponding findings, in Figs. 4 and 5, respectively. Per imaging modality, the findings are as described below.

#### $^{18}\text{F}$ -FDG-PET/CT

This pooled analysis included 6 studies comprising 254 patients. The performance characteristics were: sensitivity, 89% (95% CI 68, 97); specificity, 92% (85, 96); DOR, 95 (18, 504); positive LR, 11 (4.7, 25.0); and negative LR, 0.11 (0.03, 0.4).

#### $^{111}\text{In}$ -oxine WBC Scintigraphy

This pooled analysis included 9 studies comprising 206 patients. The performance characteristics were: sensitivity, 92% (72, 98); specificity, 75% (66, 82); DOR, 34 (6.9, 165.7); positive LR, 3.6 (1.9, 6.7); and negative LR, 0.1 (0.03, 0.4).

#### $^{99\text{m}}\text{Tc}$ -HMPAO WBC Scintigraphy

This pooled analysis included 10 studies comprising 406 patients. The performance characteristics were: sensitivity, 91% (95% CI 86, 94); specificity, 92% (78, 98); DOR, 118 (30, 459); positive LR, 12 (3.7, 36.3); and negative LR, 0.1 (0.06, 0.16).

#### MRI

This pooled analysis included 13 studies comprising 421 patients. The performance characteristics were: sensitivity, 93% (95% CI 82, 97); specificity, 75% (63, 84); DOR, 37 (11.3, 121.3); positive LR, 3.66 (2.1, 6.4); and negative LR, 0.10 (0.04, 0.26).

#### Comparison of Imaging Modalities

In summary,  $^{18}\text{F}$ -FDG-PET/CT and  $^{99\text{m}}\text{Tc}$ -HMPAO-WBC scans each had the highest specificity (92%), followed by MRI and  $^{111}\text{In}$ -oxine-WBC scan (both 75%). The sensitivity for all of the imaging modalities were similar, with MRI at 93%;  $^{111}\text{In}$ -oxine-WBC scans, 92%;  $^{99\text{m}}\text{Tc}$ -HMPAO-WBC scans, 91%; and  $^{18}\text{F}$ -FDG-PET/CT, 89%.

#### CONCLUSIONS

This meta-analysis documents the independent performance characteristics of the four imaging modalities most commonly used in the diagnosis of osteomyelitis of the foot in patients with diabetes (i.e., MRI,  $^{111}\text{In}$ -oxine-WBC SPECT/CT,  $^{99\text{m}}\text{Tc}$ -HMPAO-WBC SPECT/CT, and  $^{18}\text{F}$ -FDG-PET/CT). To the best of our knowledge, this is the first meta-analysis and systematic review that included all of these imaging modalities, allowing us to assess their comparative diagnostic values. The most relevant finding of our analysis was the higher specificity compared with other imaging techniques for both

	Risk of Bias							Applicability Concerns					
	Patient Selection	Index Test: <sup>99m</sup> Tc WBC scan	Index Test: MRI	Index Test: <sup>111</sup> In Leukocyte scan	Index Test: <sup>18</sup> F-FDG-PET scan	Reference Standard	Flow and Timing	Patient Selection	Index Test: <sup>99m</sup> Tc WBC scan	Index Test: MRI	Index Test: <sup>111</sup> In Leukocyte scan	Index Test: <sup>18</sup> F-FDG-PET scan	Reference Standard
Cook 1996	+		+			-	?	?		+			?
Crerand 1996	-			?		?	-	?			?		?
Croll 1996	+		+	+		?	-	+		+	+		?
Devillers 1998	+	?				?	+	+	?				?
Enderle 1999	-		?			+	+	?		+			+
Ertugrul 2006	?	?	+			+	+	+	+	+			+
Familiari 2011	+	+			+	+	+	+	+			+	+
Filippi 2009	+	?				?	+	+	?				?
Georga 2013	?	?	?			?	?	?	?	?			?
Harvey 1997	+	+				?	+	+	+				+
Johnson 1996	+			?		?	+	+			+		+
Kagna 2012	+				+	?	+	+				+	+
Kearney 1999	+		+			?	+	+		+			?
Keenan 1989a	?			+		-	?	?			+		?
Keidar 2005	+				+	?	+	+				+	+
La Fontaine 2016	+	+	+			+	+	+	?	+			+
Larcos 1991	?			+		?	-	?			+		+
Levine 1994	?		?	?		?	-	?		?	?		?
Maurer 1986	?			+		?	+	?			+		+
Nawaz 2010	+		+		+	?	?	+		+		+	+
Newman 1992	+		+	+		+	+	+		+	+		+
Przybylski 2016	+	+				?	?	+	+				?
Remedios 1998	+		+			?	?	+		+			+
Shagos 2015	+				+	+	-	+				+	+
Spittiger 1989	?			+		?	+	?			+		+
Unal 2001	?	-				+	+	?	-				+
Yang 2016	+				?	+	+	+				+	+
Yuh 1989	+		+			+	+	+		+			+
Zorkaltsev 2014	?	?	?			?	?	?	?	?			?



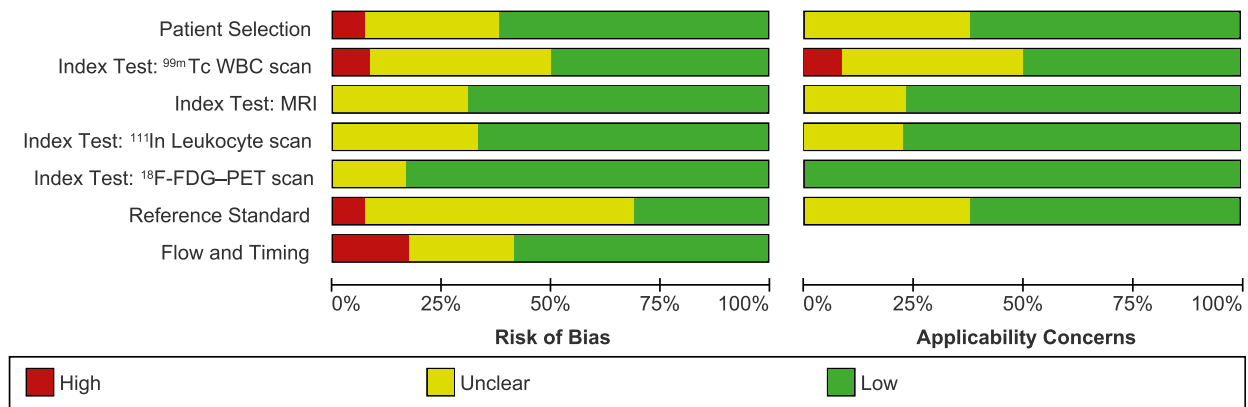
<sup>18</sup>F-FDG-PET/CT and <sup>99m</sup>Tc-HMPAO-WBC scintigraphy (with either planar or SPECT/CT acquisitions). By contrast, the sensitivity was very similar for WBC-scan, <sup>18</sup>F-FDG-PET/CT, and MRI.

The sensitivity and specificity of radio-labeled WBC reported in the articles we analyzed ranged from 75 (29) to 100% (30–32) and from 67 (32) to 100% (33), respectively. Factors that could have influenced the variations in results include: the number of patients imaged; the choice of imaging radiopharmaceutical; the acquisition protocol of the images; and the interpretation criteria followed for scan analysis (change of uptake with time and qualitative vs. semi-quantitative analysis). Only two of the articles on <sup>99m</sup>Tc-WBC (33,34) used a methodology confirmed and approved by the European Association of Nuclear Medicine (EANM) (52). In four articles (35,37,45,50), the protocols of acquisition and/or the interpretative criteria were not explained in the text. Although we are unable to make a direct comparison among these articles, the two conducted according to EANM procedural guidelines reported a sensitivity of 86 and 100% and a specificity of 100% (33,34), whereas the remaining four studies showed a lower average sensitivity and specificity (89 and 67%, respectively). If a currently approved protocol of acquisition and interpretation of images had been used, it is possible that the diagnostic accuracy would have been higher. We were unable to undertake a similar analysis for the studies of <sup>111</sup>In-labeled WBC, as all were performed with outdated imaging protocols.

Most of the studies included in our review used only planar images acquired with fixed, single times and often failed to explain the acquisition protocol. The heterogeneity in imaging protocols of acquisition and interpretation is evident for WBC scan using both <sup>99m</sup>Tc-HMPAO and <sup>111</sup>In-oxine.

In only a few studies did the authors evaluate the value of semiquantitative analysis. Nawaz et al. (24) performed an analysis in a cohort of 110 subjects studied with both <sup>18</sup>F-FDG-PET/CT and MRI. They used only visual assessment of <sup>18</sup>F-FDG uptake (without any semiquantitative analysis) and did not perform CT coregistration, which might account for the relatively low sensitivity of the technique compared with MRI (81 and 91%,

**Figure 2**—Assessment of methodological quality based on the QUADAS-2 method (patient selection, index test, reference standard, flow, and timing) for each study. Risk of bias summary and applicability concerns assessments: green, low risk; red, high risk; and yellow, unclear risk.



**Figure 3**—Assessment of methodological quality based on the QUADAS-2 method (patient selection, index test, reference standard, flow, and timing) combining all the studies. Risk of bias summary and applicability concerns assessments: green, low risk; red, high risk; and yellow, unclear risk.

respectively). Conversely, Kagna et al. (25) demonstrated the value of performing a maximum standardized uptake value evaluation and CT coregistration to precisely evaluate the extension of infection into bone and soft tissue. This study was limited, however, by the fact that microbiological confirmation of infection was only performed in two cases (Fig. 2, yellow).

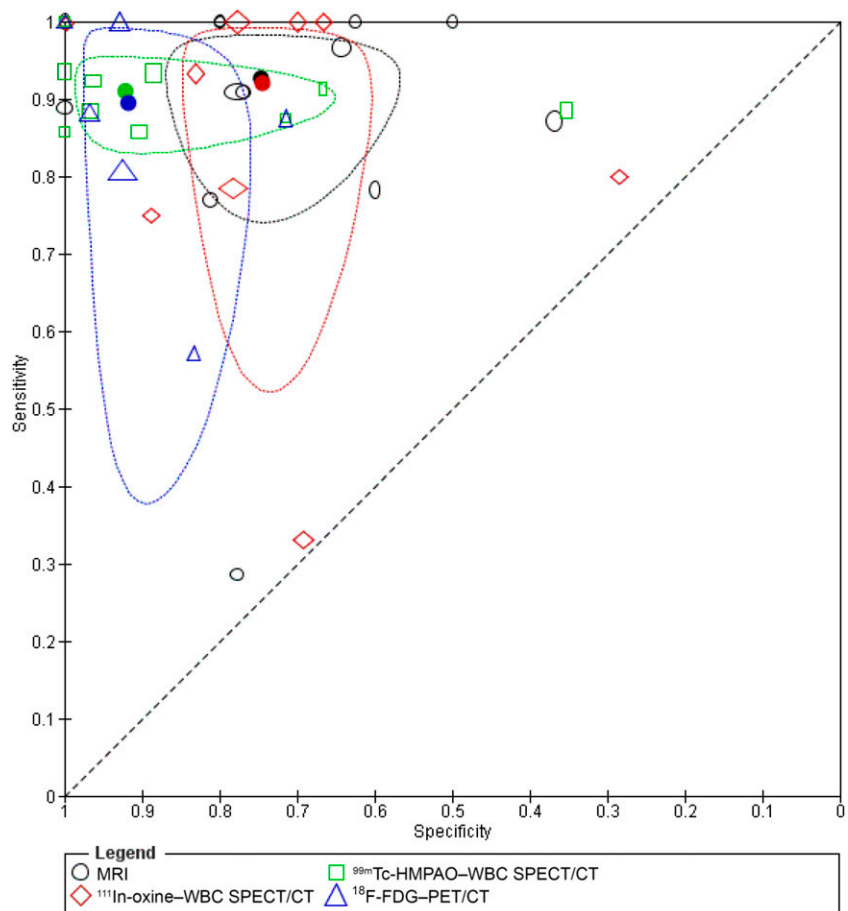
Familiari et al. (33), in accordance with EANM recommendations, used both qualitative and target/background ratio analysis and acquired images at three time points (30 min, 3 h, and 20 h post-injection), with time corrected for technetium decay. The performance characteristics for osteomyelitis (confirmed by histopathology or bone culture) using specific interpretation criteria were: sensitivity, 86%; specificity, 100%; positive predictive value; 100%, negative predictive value, 86%; and diagnostic accuracy, 92%. Similarly, Unal et al. (32) performed a target/background ratio for early and late images and found high sensitivity (94%) and specificity (100%). Other groups investigated the role of SPECT or SPECT/CT with different protocols of acquisition and, consequently, different results (34,35).

Compared with a systematic review of <sup>18</sup>F-FDG-PET/CT for diagnosing DFO published 3 years ago (53), we found a higher sensitivity with a similar specificity; this appears mainly related to their using a per-patient analysis, whereas we used a per-study analysis. Nawaz et al. (24) concluded that <sup>18</sup>F-FDG-PET/CT, although less sensitive when compared with MRI (81 vs. 91%), had higher specificity (93 vs. 78%) and diagnostic accuracy (90 vs.

81%). These results are comparable with the findings of our systematic review.

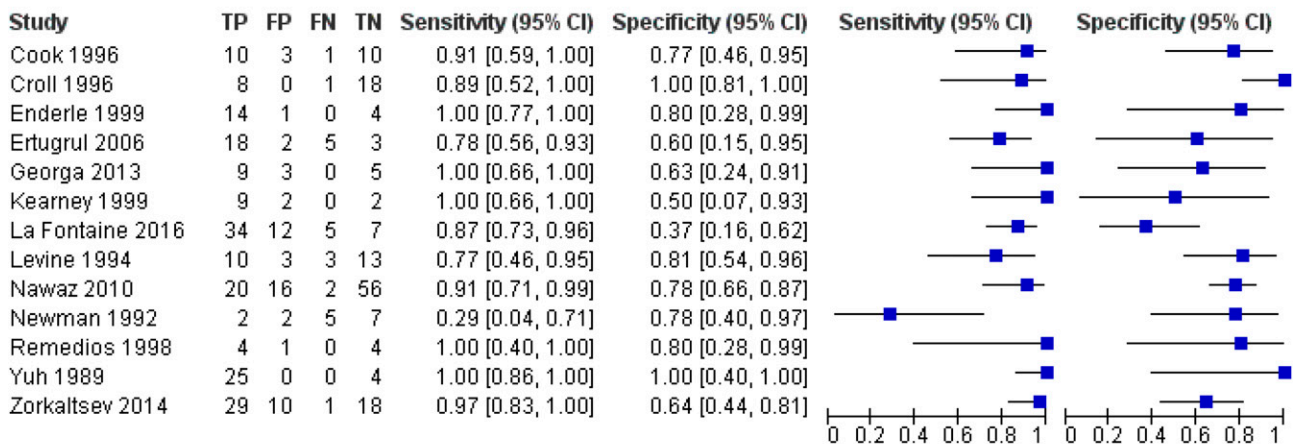
In contrast, our results differed from those in a meta-analysis by Kapoor et al.

(54) of the diagnostic performance of MRI compared with WBC scintigraphy, bone scanning, and plain radiography. They concluded that MRI was superior to

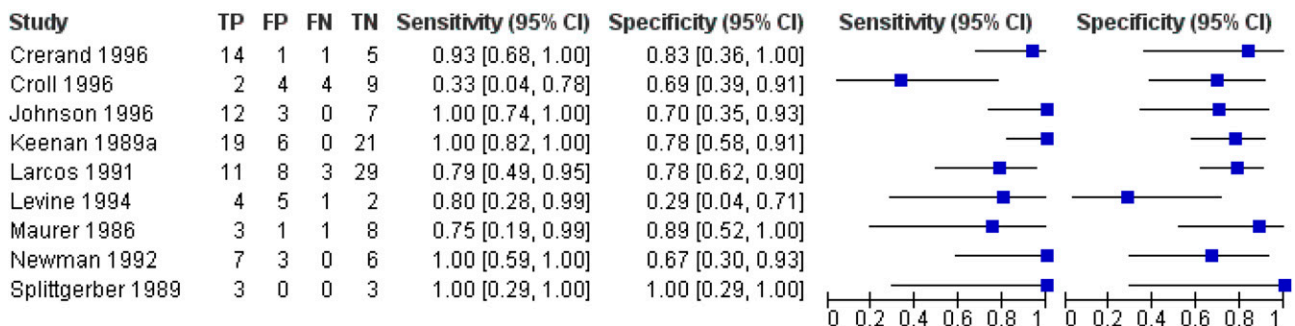


**Figure 4**—ROC curves of all studies that included each test. Thirteen studies are included for MRI (421 patients), 9 studies for <sup>111</sup>In-oxine-WBC (206 patients), 10 studies for <sup>99m</sup>Tc-HMPAO-WBC (406 patients), and 6 studies for <sup>18</sup>F-FDG-PET/CT (254 patients). The dashed colored lines are the 90% prediction intervals calculated using a bivariate hierarchical model with the STATA-13 program.

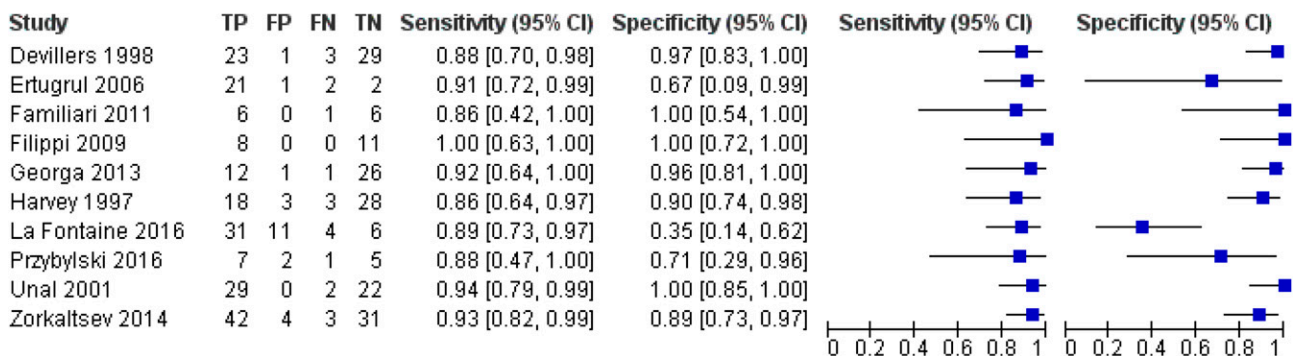
**MRI**



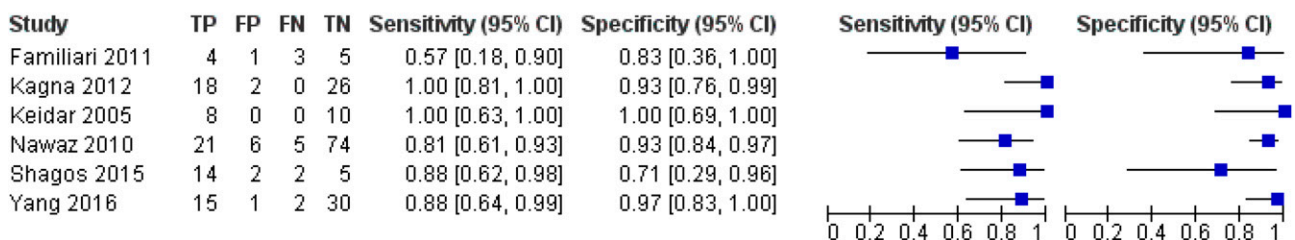
**<sup>111</sup>In WBC SPECT(CT)**



**<sup>99m</sup>Tc WBC SPECT(CT)**



**<sup>18</sup>F-FDG-PET/CT**



**Figure 5**—Forest plots (of sensitivity and specificity) of all of the studies that used each test and pooled the diagnostic performance of the imaging techniques. For each test, we have combined the sROC curves and their corresponding findings. FN, false negative; FP, false positive; TN, true negative; TP, true positive.

WBC scans, using the studies of Croll et al. (42) and Levine et al. (43). We also included these two studies, but we found a

higher specificity for WBC scan labeled with <sup>99m</sup>Tc-HMPAO than for MRI, probably because of the very small number of

WBC scans they included against MRI (only 2 out of the 17 included articles of the patients received WBC). Also, studies

of Kapoor et al. (54) are dated (>20 years old), using outdated WBC techniques (for instance, no late imaging after 24 h and lacking additional [hybrid low-dose] CT), resulting in moderate accuracy of WBC for this indication. In the future, we suggest exploring the appealing approach of hybrid imaging (55) in defining an optimal approach to imaging DFIs.

A final issue concerns the convenience of the different imaging modalities to the affected patient. In general, all modalities require that the patient be injected with a contrast agent or a radiopharmaceutical, followed by imaging with the specified scanner (PET, SPECT, or MRI). An advantage of MRI is the lack of exposure of the patient to a dose of radiation. Disadvantages of MRI include the fact that some patients experience claustrophobia in the (long) gantry and that this procedure is contraindicated in some patients who have an implanted device (e.g., implantable cardioverter defibrillator or cardiac pacemakers). Furthermore, the specificity of MRI is decreased by metal scatter in patients who have metallic hardware (e.g., screws or plates) in situ at the suspected site of infection. A key disadvantage of PET and SPECT are that they impart a radiation dose to the patient. Furthermore, these procedures are in general more expensive than MRI. The cost of each procedure is an important concern, not only for the patient but also for the health care system. Cost will, however, vary considerably over time, by the specific procedures used, and depending on the health care system and insurance issues germane to the patient under treatment. Furthermore, there is a difference between the actual cost and price (or charge) for any diagnostic test. For example, in many centers in the U.S., the amount charged for imaging tests is much higher than their costs, with the profits often used to offset losses related to other aspects of care.

### Limitations

Unfortunately, because of the limited number of published articles, we could not analyze the value of using antibodies against granulocytes (either whole IgG or F[ab] fragment), despite the fact that they are now routinely used in some nuclear medicine centers (16–18). In fact, the number of patients included in all of the available studies was relatively small,

ranging from 6 to 110, with most enrolling <20. This leads to wide CIs, making comparisons between different techniques difficult and subgroup analyses or meta-regression impossible. Additionally, direct comparisons of all available imaging techniques within the same patient groups were not available, as none of the studies compared all four of the different techniques in the same study.

Many studies used the dual reference standard for osteomyelitis of clinical follow-up for test-negative patients and bone biopsy with subsequent pathological examination for test-positive patients. Despite the potential for introducing bias, we included all of these studies, as excluding them would significantly reduce the number of articles available, precluding performing a comparison among tests. We also believe that this approach is more representative of what is widely done in clinical practice.

As mentioned earlier, a key problem in diagnosing DFO is differentiating it from neuro-osteoarthropathy (Charcot foot) (56). Although some studies included Charcot foot as a separate diagnosis from soft tissue infection and osteomyelitis, we elected to leave this issue for a future review. Another factor is that the published articles often failed to provide information on the patients' use of antibiotics or anti-inflammatory drugs and on their control of glucose levels. Thus, we cannot define the optimum time for imaging following antibiotic therapy or the possible effects of antibiotic or anti-inflammatory treatment, or glycemic control, on WBC or  $^{18}\text{F}$ -FDG-PET/CT scans. However, three prospective studies (57–59) have concluded that WBC scintigraphy performed under (or just after) antibiotic treatment retains a high sensitivity and specificity, perhaps even greater than for MRI for detecting residual disease (57). A retrospective study of 297 patients with suspected osteomyelitis or soft tissue infection by Glaudemans et al. (60), although not focused on the diabetic foot, suggested that there were no significant differences in performance results of WBC scintigraphy results between patients who were and those who were not receiving antibiotic therapy. We are unable to assess the possible effect of hyperglycemia on  $^{18}\text{F}$ -FDG-PET/CT findings, as glucose levels were often missing in the retrieved articles. In one study, however, hyperglycemia in a

fasting state did not appear to significantly influence the quality of  $^{18}\text{F}$ -FDG-PET/CT imaging (61). Despite all of these limitations, including some biases, in general, there will be a preference for  $^{99\text{m}}\text{Tc}$ -HMPAO-labeled WBC scintigraphy and  $^{18}\text{F}$ -FDG-PET/CT, which are both techniques that proved their value in many other infectious diseases and offer the best highest specificity for diagnosing DFO. Sensitivity results were comparable among all imaging modalities.

### Conclusion

Our systematic review and meta-analysis suggest that  $^{99\text{m}}\text{Tc}$ -HMPAO-labeled WBC scintigraphy and  $^{18}\text{F}$ -FDG-PET/CT offer the highest specificity for diagnosing DFO while demonstrating comparable sensitivity to the other imaging techniques we reviewed (MRI and WBC scintigraphy with  $^{111}\text{In}$ -oxine). In view of the continued lack of consensus on this issue, we believe there is a need for a standardization of diagnostic methods and an evidence-based sequential approach. Selecting the most appropriate imaging test in any clinical situation depends upon the particular circumstances of the patient, the expertise, and equipment available at the treating site and the costs of the procedures. The goal is certainly to use the most cost-effective imaging method to allow accurate diagnosis and prompt treatment of this common, complex, and costly problem. This will require further prospective studies with larger numbers of patients and with a direct comparison between the different radiological and nuclear medicine techniques.

---

**Acknowledgments.** The authors thank N. Smidt for assistance and general advice for the review, S. van der Werf for helping conduct the literature searches, and Y. Takwoingi and M. Leeflang (all from the University Medical Center Groningen) for assisting with the data analyses and statistical evaluations.

**Funding.** R.H.J.A.S. is the recipient of a research grant from the University Medical Center Groningen Healthy Aging Pilot Fund.

**Duality of Interest.** No potential conflicts of interest relevant to this article were reported.

**Author Contributions.** C.L. analyzed data and wrote the manuscript. M.T. analyzed data and reviewed the manuscript. A.W.J.M.G. designed the study and wrote and reviewed the manuscript. L.E.J.O. analyzed data and edited the manuscript. P.A.E. reviewed the manuscript. P.C.J. designed the study and wrote and reviewed the manuscript.



B.A.L. reviewed and edited the manuscript. M.J.I. analyzed the data and reviewed the manuscript. A.S. reviewed the manuscript. R.H.J.A.S. designed the study and wrote, edited, and reviewed the manuscript. R.H.J.A.S. is the guarantor of this work and, as such, had full access to all the data in the study and takes responsibility for the integrity of the data and the accuracy of the data analysis.

## References

1. Markakis K, Bowling FL, Boulton AJ. The diabetic foot in 2015: an overview. *Diabetes Metab Res Rev* 2016;32(Suppl. 1):169–178
2. Zhang P, Lu J, Jing Y, Tang S, Zhu D, Bi Y. Global epidemiology of diabetic foot ulceration: a systematic review and meta-analysis (†). *Ann Med* 2017;49:106–116
3. Lipsky BA, Aragón-Sánchez J, Diggle M, et al.; International Working Group on the Diabetic Foot. IWGDF guidance on the diagnosis and management of foot infections in persons with diabetes. *Diabetes Metab Res Rev* 2016;32(Suppl. 1):45–74
4. Brennan MB, Hess TM, Bartle B, et al. Diabetic foot ulcer severity predicts mortality among veterans with type 2 diabetes. *J Diabetes Complications*. 2017;31:556–561
5. Lavery LA, Armstrong DG, Wunderlich RP, Mohler MJ, Wendel CS, Lipsky BA. Risk factors for foot infections in individuals with diabetes. *Diabetes Care* 2006;29:1288–1293
6. Prompers L, Huijberts M, Apelqvist J, et al. High prevalence of ischaemia, infection and serious comorbidity in patients with diabetic foot disease in Europe. Baseline results from the Eurodiale study. *Diabetologia* 2007;50:18–25
7. Lipsky BA. Osteomyelitis of the foot in diabetic patients. *Clin Infect Dis* 1997;25:1318–1326
8. Ramanujam CL, Zgonis T. The diabetic charcot foot from 1936 to 2016: eighty years later and still srowing. *Clin Podiatr Med Surg* 2017;34:1–8
9. Kucera T, Shaikh HH, Sponer P. Charcot neuropathic arthropathy of the foot: a literature review and single-center experience. *J Diabetes Res* 2016;2016:3207043
10. Berendt AR, Peters EJ, Bakker K, et al. Diabetic foot osteomyelitis: a progress report on diagnosis and a systematic review of treatment. *Diabetes Metab Res Rev* 2008;24(Suppl. 1):S145–S161
11. Lam K, van Asten SA, Nguyen T, La Fontaine J, Lavery LA. Diagnostic accuracy of probe to bone to detect osteomyelitis in the diabetic foot: a systematic review. *Clin Infect Dis* 2016; 63:944–948
12. van Asten SA, Jupiter DC, Mithani M, La Fontaine J, Davis KE, Lavery LA. Erythrocyte sedimentation rate and C-reactive protein to monitor treatment outcomes in diabetic foot osteomyelitis. *Int Wound J* 2017;14:142–148
13. Palestro CJ, Love C. Nuclear medicine and diabetic foot infections. *Semin Nucl Med* 2009;39: 52–65
14. Israel O, Sconfienza LM, Lipsky BA. Diagnosing diabetic foot infection: the role of imaging and a proposed flow chart for assessment. *QJ Nucl Med Mol Imaging* 2014;58:33–45
15. Lipsky BA, Berendt AR, Cornia PB, et al.; Infectious Diseases Society of America. 2012 Infectious Diseases Society of America clinical practice guideline for the diagnosis and treatment of diabetic foot infections. *Clin Infect Dis* 2012;54: e132–e173
16. Palestro CJ, Caprioli R, Love C, et al. Rapid diagnosis of pedal osteomyelitis in diabetics with a technetium-99m-labeled monoclonal anti-granulocyte antibody. *J Foot Ankle Surg* 2003;42: 2–8
17. Delcourt A, Huglo D, Prangere T, et al. Comparison between Leukoscan (Sulesomab) and Gallium-67 for the diagnosis of osteomyelitis in the diabetic foot. *Diabetes Metab* 2005;31:125–133
18. Harwood SJ, Valdivia S, Hung GL, Quenzer RW. Use of Sulesomab, a radiolabeled antibody fragment, to detect osteomyelitis in diabetic patients with foot ulcers by leukoscintigraphy. *Clin Infect Dis* 1999;28:1200–1205
19. Whiting PF, Rutjes AW, Westwood ME, et al.; QUADAS-2 Group. QUADAS-2: a revised tool for the quality assessment of diagnostic accuracy studies. *Ann Intern Med* 2011;155:529–536
20. Moher D, Liberati A, Tetzlaff J, Altman DG; PRISMA Group. Preferred reporting items for systematic reviews and meta-analyses: the PRISMA statement. *PLoS Med* 2009;6:e1000097
21. Higgins JPT, Thompson SG. Quantifying heterogeneity in a meta-analysis. *Stat Med* 2002;21: 1539–1558
22. Higgins JPT, Thompson SG, Deeks JJ, Altman DG. Measuring inconsistency in meta-analyses. *BMJ* 2003;327:557–560
23. Enderle MD, Coerper S, Schweizer HP, et al. Correlation of imaging techniques to histopathology in patients with diabetic foot syndrome and clinical suspicion of chronic osteomyelitis. *Diabetes Care* 1999;22:294–299
24. Nawaz A, Torigian DA, Siegelman ES, Basu S, Chryssikos T, Alavi A. Diagnostic performance of FDG-PET, MRI, and plain film radiography (PFR) for the diagnosis of osteomyelitis in the diabetic foot. *Mol Imaging Biol* 2010;12:335–342
25. Kagna O, Srour S, Melamed E, Militianu D, Keidar Z. FDG PET/CT imaging in the diagnosis of osteomyelitis in the diabetic foot. *Eur J Nucl Med Mol Imaging* 2012;39:1545–1550
26. Keidar Z, Militianu D, Melamed E, Bar-Shalom R, Israel O. The diabetic foot: initial experience with 18F-FDG PET/CT. *J Nucl Med* 2005;46:444–449
27. Shagos GS, Shanmugasundaram P, Varma AK, Padma S, Sarma M. 18-F fluorodeoxy glucose positron emission tomography-computed tomography imaging: a viable alternative to three phase bone scan in evaluating diabetic foot complications? *Indian J Nucl Med* 2015;30:97–103
28. Maurer AH, Millmond SH, Knight LC, et al. Infection in diabetic osteoarthropathy: use of indium-labeled leukocytes for diagnosis. *Radiology* 1986;161:221–225
29. Keenan AM, Tindel NL, Alavi A. Diagnosis of pedal osteomyelitis in diabetic patients using current scintigraphic techniques. *Arch Intern Med* 1989;149:2262–2266
30. Johnson JE, Kennedy EJ, Shereff MJ, Patel NC, Collier BD. Prospective study of bone, indium-111-labeled white blood cell, and gallium-67 scanning for the evaluation of osteomyelitis in the diabetic foot. *Foot Ankle Int* 1996;17:10–16
31. Newman LG, Waller J, Palestro CJ, et al. Leukocyte scanning with <sup>111</sup>In is superior to magnetic resonance imaging in diagnosis of clinically unsuspected osteomyelitis in diabetic foot ulcers. *Diabetes Care* 1992;15:1527–1530
32. Unal SN, Birinci H, Baktiroğlu S, Cantez S. Comparison of Tc-99m methylene diphosphonate, Tc-99m human immune globulin, and Tc-99m-labeled white blood cell scintigraphy in the diabetic foot. *Clin Nucl Med* 2001;26:1016–1021
33. Familiari D, Glaudemans AW, Vitale V, et al. Can sequential <sup>18</sup>F-FDG PET/CT replace WBC imaging in the diabetic foot? *J Nucl Med* 2011;52: 1012–1019
34. Filippi L, Uccioli L, Giurato L, Schillaci O. Diabetic foot infection: usefulness of SPECT/CT for <sup>99m</sup>Tc-HMPAO-labeled leukocyte imaging. *J Nucl Med* 2009;50:1042–1046
35. Przybylski MM, Holloway S, Vyce SD, Obando A. Diagnosing osteomyelitis in the diabetic foot: a pilot study to examine the sensitivity and specificity of Tc(99m) white blood cell-labelled single photon emission computed tomography/computed tomography. *Int Wound J* 2016;13: 382–389
36. Larcos G, Brown ML, Sutton RT. Diagnosis of osteomyelitis of the foot in diabetic patients: value of <sup>111</sup>In-leukocyte scintigraphy. *AJR Am J Roentgenol* 1991;157:527–531
37. Devillers A, Moisan A, Hennion F, Garin E, Poirier JY, Bourguet P. Contribution of technetium-99m hexamethylpropylene amine oxime labelled leukocyte scintigraphy to the diagnosis of diabetic foot infection. *Eur J Nucl Med* 1998;25: 132–138
38. Crerand S, Dolan M, Laing P, Bird M, Smith ML, Klenerman L. Diagnosis of osteomyelitis in neuropathic foot ulcers. *J Bone Joint Surg Br* 1996; 78:51–55
39. Splittgerber GF, Spiegelhoff DR, Buggy BP. Combined leukocyte and bone imaging used to evaluate diabetic osteoarthropathy and osteomyelitis. *Clin Nucl Med* 1989;14:156–160
40. Harvey J, Cohen MM. Technetium-99-labeled leukocytes in diagnosing diabetic osteomyelitis in the foot. *J Foot Ankle Surg* 1997;36:209–214; discussion 256
41. Georga S, Manes C, Lo-Presti D, et al. SPECT/CT value in the diagnosis of diabetic foot infections by 99mTc-HMPAO-labeled leukocyte scan. *Eur J Nucl Med Mol Imaging* 2015;42(Suppl. 1): S790–S791
42. Croll SD, Nicholas GG, Osborne MA, Wasser TE, Jones S. Role of magnetic resonance imaging in the diagnosis of osteomyelitis in diabetic foot infections. *J Vasc Surg* 1996;24:266–270
43. Levine SE, Neagle CE, Esterhai JL, Wright DG, Dalinka MK. Magnetic resonance imaging for the diagnosis of osteomyelitis in the diabetic patient with a foot ulcer. *Foot Ankle Int* 1994;15:151–156
44. Remedios D, Valabhji J, Oelbaum R, Sharp P, Mitchell R. <sup>99m</sup>Tc-nanocolloid scintigraphy for assessing osteomyelitis in diabetic neuropathic feet. *Clin Radiol* 1998;53:120–125
45. Ertugrul MB, Baktiroglu S, Salman S, et al. The diagnosis of osteomyelitis of the foot in diabetes: microbiological examination vs. magnetic resonance imaging and labelled leukocyte scanning. *Diabet Med* 2006;23:649–653
46. Kearney T, Pointin K, Cunningham D, Gedroyc W, Robinson S, Elkeles RS. The detection of pedal osteomyelitis in diabetic patients. *Practical Diabetes Int* 1999;16:98–100
47. Cook TA, Rahim N, Simpson HC, Galland RB. Magnetic resonance imaging in the management

- of diabetic foot infection. *Br J Surg* 1996;83:245–248
48. Yuh WT, Corson JD, Baraniewski HM, et al. Osteomyelitis of the foot in diabetic patients: evaluation with plain film,  $^{99m}\text{Tc}$ -MDP bone scintigraphy, and MR imaging. *AJR Am J Roentgenol* 1989;152:795–800
49. Yang H, Zhuang H, Rubello D, Alavi A. Mild-to-moderate hyperglycemia will not decrease the sensitivity of  $^{18}\text{F}$ -FDG PET imaging in the detection of pedal osteomyelitis in diabetic patients. *Nucl Med Commun* 2016;37:259–262
50. La Fontaine J, Bhavan K, Lam K, et al. Comparison between Tc-99m WBC SPECT/CT and MRI for the diagnosis of biopsy-proven diabetic foot osteomyelitis. *Wounds* 2016;28:271–278
51. Zorkaltsev M, Zavadovskaya V, Udodov V, Zamyshvskaya M, Grigoryev E, Kurazhov A. Radiolabeled WBC-scintigraphy versus magnetic resonance imaging and bone scintigraphy in diabetic patients with suspected osteomyelitis of the foot. *Eur J Nucl Med Mol Imaging* 2014;41(Suppl. 2):S590–S591
52. Erba PA, Glaudemans AW, Veltman NC, et al. Image acquisition and interpretation criteria for  $^{99m}\text{Tc}$ -HMPAO-labelled white blood cell scintigraphy: results of a multicentre study. *Eur J Nucl Med Mol Imaging* 2014;41:615–623
53. Treglia G, Sadeghi R, Annunziata S, et al. Diagnostic performance of fluorine-18-fluorodeoxyglucose positron emission tomography for the diagnosis of osteomyelitis related to diabetic foot: a systematic review and a meta-analysis. *Foot* 2013;23:140–148
54. Kapoor A, Page S, Lavalley M, Gale DR, Felson DT. Magnetic resonance imaging for diagnosing foot osteomyelitis: a meta-analysis. *Arch Intern Med* 2007;167:125–132
55. Knešaurek K, Kolker D, Vatti S, Heiba S. Precise fusion of MRI and dual energy  $^{111}\text{In}$  WBC/ $^{99m}\text{Tc}$  HDP SPECT/CT in the diabetic foot using companion CT: an example of SPECT/MRI imaging. *Q J Nucl Med Mol Imaging* 2015;59:129–135
56. Ertugrul BM, Lipsky BA, Savk O. Osteomyelitis or Charcot neuro-osteoarthropathy? Differentiating these disorders in diabetic patients with a foot problem. *Diabet Foot Ankle* 2013;5:4
57. Vesco L, Boulahdour H, Hamissa S, et al. The value of combined radionuclide and magnetic resonance imaging in the diagnosis and conservative management of minimal or localized osteomyelitis of the foot in diabetic patients. *Metabolism* 1999;48:922–927
58. Lazaga F, Van Asten SA, Nichols A, et al. Hybrid imaging with  $^{99m}\text{Tc}$ -WBC SPECT/CT to monitor the effect of therapy in diabetic foot osteomyelitis. *Int Wound J* 2016;13:1158–1160
59. Newman LG, Waller J, Palestro CJ, et al. Un-suspected osteomyelitis in diabetic foot ulcers. Diagnosis and monitoring by leukocyte scanning with indium in 111 oxyquinoline. *JAMA* 1991;266:1246–1251
60. Glaudemans AW, de Vries EF, Vermeulen LE, Slart RH, Dierckx RA, Signore A. A large retrospective single-centre study to define the best image acquisition protocols and interpretation criteria for white blood cell scintigraphy with  $^{99m}\text{Tc}$ -HMPAO-labelled leucocytes in musculoskeletal infections. *Eur J Nucl Med Mol Imaging* 2013;40:1760–1769
61. Rabkin Z, Israel O, Keidar Z. Do hyperglycemia and diabetes affect the incidence of false-negative  $^{18}\text{F}$ -FDG PET/CT studies in patients evaluated for infection or inflammation and cancer? A comparative analysis. *J Nucl Med* 2010;51:1015–1020