



Since January 2020 Elsevier has created a COVID-19 resource centre with free information in English and Mandarin on the novel coronavirus COVID-19. The COVID-19 resource centre is hosted on Elsevier Connect, the company's public news and information website.

Elsevier hereby grants permission to make all its COVID-19-related research that is available on the COVID-19 resource centre - including this research content - immediately available in PubMed Central and other publicly funded repositories, such as the WHO COVID database with rights for unrestricted research re-use and analyses in any form or by any means with acknowledgement of the original source. These permissions are granted for free by Elsevier for as long as the COVID-19 resource centre remains active.

Transplant & Mechanical Support: Case Report

Successful Lung Transplantation From a Donor With Previous Severe COVID-19 Pneumonia



Stefania Camagni, MD,¹
 Fabiano Di Marco, MD, PhD,^{2,3}
 Emanuele Sani, MD,⁴ Marta Beretta, MD,²
 Francesco Legittimo, MD,⁵
 Domenico Pinelli, MD,¹ and
 Michele Colledan, MD, FEBS^{1,6}

Lungs from donors with previous COVID-19 could become a precious resource if proved safe. So far, only 3 successful lung transplantations from donors with previous mild COVID-19 have been reported. We describe a successful bilateral sequential lung transplantation from a donor who, 10 months before, had developed severe COVID-19 acute respiratory distress syndrome. No donor-derived viral transmission occurred, and 12 months after transplantation, the recipient's lung function is normal. In the presence of normal results of bronchoalveolar lavage and adequate functional and morphologic parameters, even a history of severe COVID-19 acute respiratory distress syndrome might not be considered a contraindication to lung donation.

(Ann Thorac Surg Short Reports 2023;1:182-184)

© 2022 The Authors. Published by Elsevier Inc. on behalf of
 The Society of Thoracic Surgeons. This is an open
 access article under the CC BY-NC-ND license
 (<http://creativecommons.org/licenses/by-nc-nd/4.0/>).

The safety of transplanting lungs from donors with previous COVID-19 is currently under investigation. The main concerns are the possible risk of donor-derived viral transmission and the possible impairment of graft quality. Ceulemans and coworkers,¹ who pioneered this approach, encouraged transplant centers to share their experience with this issue. So far, to our knowledge, 3

successful lung transplantations from donors with resolved mild COVID-19 have been reported.¹⁻⁴ We describe a successful bilateral sequential lung transplantation from a donor with previous severe COVID-19 acute respiratory distress syndrome (ARDS).

The donor was a 51-year-old nonsmoker. Ten months before the cerebrovascular accident leading to brain death, when COVID-19 vaccines were not available, he developed severe COVID-19 ARDS (Figure A). He was admitted to the intensive care unit (ICU), where he was supported with mechanical ventilation for 5 days and was treated with corticosteroids and remdesivir. He did not have extrapulmonary complications. At discharge, after a 7-day ICU stay and a 15-day hospital stay, he was still in need of supplemental oxygen. Subsequently, he gradually returned to his pre-COVID conditions, apparently with no long COVID symptoms, and received 2 doses of mRNA BNT162b2 (Comirnaty) vaccine. Eight months after discharge, the follow-up spirometry measurement was normal. At the time of donation, the bronchoalveolar lavage fluid tested negative for SARS-CoV-2 by polymerase chain reaction (PCR), the best PaO₂/Fio₂ was 415, and chest radiography (Figure B) and bronchoscopy findings appeared normal. At procurement, macroscopic lung appearance and compliance were normal.

The recipient was a 57-year-old woman with end-stage bronchiolitis obliterans syndrome due to chronic graft-versus-host disease after allogeneic stem cell transplantation, receiving continuous long-term oxygen therapy. She had previously been administered 2 doses of mRNA-1273 (Moderna) vaccine; at the time of transplantation, the nasopharyngeal swab tested negative for SARS-CoV-2 by PCR. She was informed of the donor's history of COVID-19, but no specific consent was required by our national guidelines.⁵

The bilateral sequential lung transplantation was uncomplicated. The patient received standard induction therapy with basiliximab and standard maintenance immunosuppressive therapy with tacrolimus, corticosteroids, and azathioprine. She was extubated 12 hours after transplantation and discharged from the ICU 5 days later. The subsequent course was complicated by *Pseudomonas aeruginosa* pneumonia, successfully treated with antibiotics, and by right bronchial stenosis (location a and extent b, according to the grading system proposed by the International Society for Heart and Lung

Accepted for publication Oct 17, 2022.

¹Department of Organ Failure and Transplantation, ASST Papa Giovanni XXIII, Bergamo, Italy; ²Respiratory Unit, ASST Papa Giovanni XXIII, Bergamo, Italy; ³Università degli Studi di Milano, Milano, Italy; ⁴Department of Anesthesia and Intensive Care, Parma University Hospital, Parma, Italy; ⁵Department of Anesthesia and Intensive Care, Guastalla Hospital, Reggio Emilia, Italy; and ⁶Università degli Studi di Milano-Bicocca, Milano, Italy
 Address correspondence to Dr Camagni, Department of Organ Failure and Transplantation, ASST Papa Giovanni XXIII, Piazza OMS 1, 24127 Bergamo, Italy; email: scamagni@asst-pg23.it.

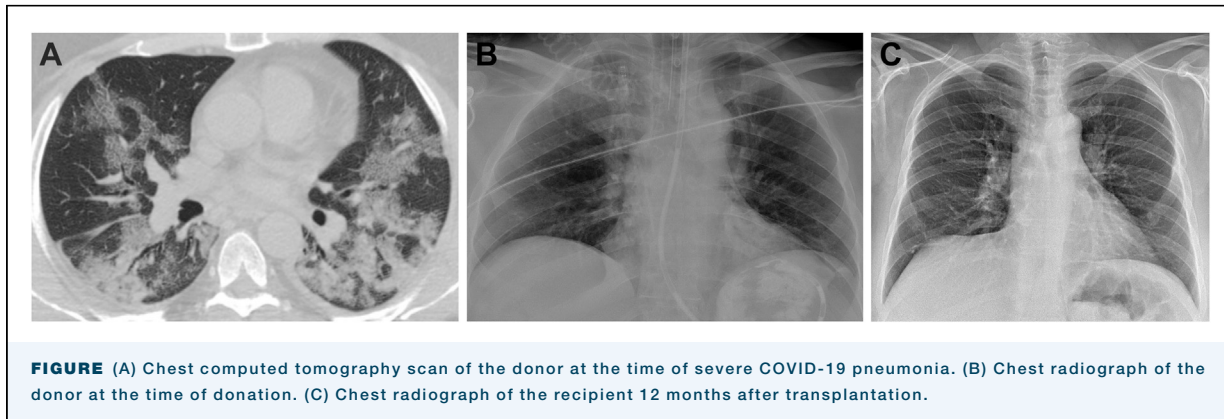


FIGURE (A) Chest computed tomography scan of the donor at the time of severe COVID-19 pneumonia. (B) Chest radiograph of the donor at the time of donation. (C) Chest radiograph of the recipient 12 months after transplantation.

Transplantation⁶) and malacia (location a), requiring endoscopic toilet and dilation. The patient was discharged to home 47 days after transplantation, with no need for supplemental oxygen.

Posttransplantation surveillance nasopharyngeal swabs tested negative for SARS-CoV-2 by PCR until the fifth month after transplantation, when the Omicron variant was detected. The patient remained fully asymptomatic. The endoscopic appearance of the right bronchial anastomosis progressively improved, and at the last check, 10 months after transplantation, stenosis or malacia was not detected.

Twelve months after transplantation, the patient is breathing ambient air, and blood gas values are normal. Forced expiratory volume in 1 second and forced vital capacity are normal (92% and 97% of predicted, respectively), and the chest radiograph is clear (Figure C).

COMMENT

This report describes a successful lung transplantation from a donor with previous severe COVID-19 ARDS. Considering the normal results of the donor's bronchoalveolar lavage and the long interval since the donor's infection with SARS-CoV-2, there was virtually no risk of donor-derived viral transmission.⁵ In the recipient, the infection with the Omicron variant was most likely de novo. As a matter of fact, the Omicron variant was detected in the recipient's nasopharyngeal swab 4 months after transplantation, after several consecutive negative test results. Besides that, the Omicron variant was first reported to the World Health Organization 12 months after the donor's infection.

It is difficult to predict the respiratory consequences of COVID-19, and the possible development of lung fibrosis is a reasonable concern. However, the rate of

long-term, irreversible fibrotic scarring seems to be low, and the rate of progressive fibrosis seems to be even lower, also in ARDS patients.⁷ In Italy, the mandatory testing for deceased lung donors does not include computed tomography (CT) scan, which may be performed at the discretion of the donor hospital. In the case reported, the transplant center was informed of the donor's history of COVID-19 only at the very time of procurement. A CT scan had not previously been obtained and unfortunately could not be performed at that moment. Nevertheless, given the encouraging available data, its unavailability was not deemed a limitation to a proper evaluation. A careful intraoperative assessment of lung morphology, compliance, and function, as recommended,⁵ allowed us to reasonably confirm the good quality of the graft. Furthermore, the prognostic value of CT scan in the follow-up of patients with previous COVID-19 is still unknown.⁷ Basically, in the face of organ shortage, we do not consider the unavailability of a CT scan a contraindication to the evaluation of an otherwise potentially suitable donor.

A possible contribution of the donor infection with SARS-CoV-2 to the pathogenesis of the airway complication in the recipient cannot be excluded. However, findings on donor bronchoscopy at the time of donation were normal. Moreover, posttransplantation airway complication rates were reported to be up to 18%, and multiple risk factors were identified.⁶

Twenty-two months after severe COVID-19 ARDS and 12 months after transplantation, these lungs perform satisfactorily. Because of the broad diffusion of COVID-19, selected lung donors with previous SARS-CoV-2 infection may reasonably become a precious resource. In the presence of adequate functional and morphologic parameters, even a history of severe COVID-19 ARDS might not be considered a contraindication to lung donation.

The authors wish to thank the donor family, the team involved in the organ donation program at Parma University Hospital, and the team involved in the lung transplant program at ASST Papa Giovanni XXIII.

FUNDING SOURCES

The authors have no funding sources to disclose.

DISCLOSURES

The authors have no conflicts of interest to disclose.

PATIENT CONSENT

Obtained.

REFERENCES

1. Ceulemans LJ, Van Slambrouck J, De Leyn P, et al. Successful double-lung transplantation from a donor previously infected with SARS-CoV-2. *Lancet Respir Med*. 2021;9:315-318.
 2. Ceulemans LJ, Khan M, Yoo SJ, et al. Persistence of SARS-CoV-2 RNA in lung tissue after mild COVID-19. *Lancet Respir Med*. 2021;9:e78-e79.
 3. Querrey M, Kurihara C, Manerikar A, et al. Lung donation following SARS-CoV-2 infection. *Am J Transplant*. 2021;21:4073-4078.
 4. Kim HJ, Shin DH, Cho WH, Kim D, Yeo HJ. Successful lung transplantation from a donor who had recovered from SARS-CoV-2 pneumonia. *Ann Thorac Surg*. 2022;113:e351-e354.
 5. Nota CNT prot. n. 20696/CNT del 31.05. 2021. Accessed January 29, 2022. https://www.trapianti.salute.gov.it/imgs/C_17_cntAvvisi_320_0_file.pdf
 6. Crespo MM, McCarthy DP, Hopkins PM, et al. ISHLT Consensus Statement on adult and pediatric airway complications after lung transplantation: definitions, grading system, and therapeutics. *J Heart Lung Transplant*. 2018;37:548-563.
 7. Martini K, Larici AR, Revel MP, et al. COVID-19 pneumonia imaging follow-up: when and how? A proposition from ESTI and ESR. *Eur Radiol*. 2022;32:2639-2649.
-